T113
+Y12
2090

THE USE OF FETAL ELECTROCARDIOGRAPHY IN THE EVALUATION OF FETAL DISTRESS AND THE DETECTION OF FETAL VIABILITY

Jack Levin

1957

MUDD
LIBRARY
Medical

YALE

MEDICAL LIBRARY

Digitized by the Internet Archive
in 2017 with funding from
Arcadia Fund

https://archive.org/details/useoffetalelectr00levi

THE USE OF FETAL ELECTROCARDIOGRAPHY IN THE EVALUATION OF FETAL DISTRESS AND THE DETECTION OF FETAL VIABILITY

by

Jack Levin, B.A.
Yale University, 1953

A Thesis Presented to the Faculty
of the Yale University School of Medicine
in Partial Fulfillment of the Requirements for the
Degree of Doctor of Medicine

The Department of Obstetrics and Gynecology
Yale University School of Medicine
1957

AUG 1951
LIBRARY

T 113
Y12
2090

DEDICATION

To my Parents, Teachers, and Friends

All of whom, in their respective ways,
have contributed to my education.

ACKNOWLEDGMENTS

The author is very grateful to Dr. E. H. G. Hon, Assistant Professor of Obstetrics and Gynecology, under whose direction and guidance this study was carried out. He was more than generous with both help and advice; and from him, the author learned the application of scientific rationale and techniques to clinical investigation.

Miss Jacquelyn Corbett drew the graphs, assisted in the production of the illustrations, and transformed a battered manuscript into a finished paper. Miss Frances Douglas obtained many of the tracings that are shown here, and Mr. George Park built much of the equipment that was used. The author wishes to express his gratitude to them for the many long hours they spent to make this project possible.

This study was aided in part by a
Josiah H. Macy, Jr. Foundation Fellowship

TABLE OF CONTENTS

	Page
DEDICATION	ii
ACKNOWLEDGMENTS	iii
HISTORY AND INTRODUCTION	1
SURVEY	19
BASIC CONSIDERATIONS	22
Technical	22
Clinical	26
MATERIALS AND METHODS	30
Diagnosis of fetal viability and related study	30
Fetal heart rate and rhythm studies	34
RESULTS	40
Fetal viability	41
Multiple pregnancy	47
Presentation of the fetus	52
Configuration of the fetal electrocardiogram	52
Fetal bradycardia	57
Miscellaneous	59
Fetal heart rate studies during labor	61
DISCUSSION	67
SUMMARY AND CONCLUSIONS	69
BIBLIOGRAPHY	70

LIST OF FIGURES

Figures		Page
1	Block diagram of equipment	32
2	Uncancelled fetal electrocardiogram	32
3	Use of a decade counter	37
4	Block diagram of semi-automatic data reduction system	37
5	Stages in data processing	38
6A	Fetal viability: fetal death	44
6B	Fetal viability: fetal death	45
7A	Fetal viability: fetal life	48
7B	Fetal viability: fetal life	49
8	Multiple pregnancies	51
9	Presentation of the fetus	53
10	Abnormal fetal electrocardiogram configurations	56
11	Fetal bradycardia	58
12	Graph of fetal bradycardia	60
13	Rapid impulses of unknown significance	62
14	Fetal heart rate in early labor: vertex	64
15	Fetal heart rate in late labor: vertex	64
16	Fetal heart rate in late labor: breech	65

HISTORY AND INTRODUCTION

HISTORY AND INTRODUCTION

Interest in the fetal heart goes back to at least the time of the introduction of the stethoscope into clinical medicine by Laennec in 1819. Prior to that time, there were only two accounts of anyone listening to the fetal heart. Around 1650 in Niort, France, a local physician, Phillipe Le Goust, in a poem, made fun of his friend Marsac for claiming to hear the heart of the fetus "beating like the clapper of a mill". About 150 years later, Francois-Isaac Mayor of Geneva is said to have listened to the fetal heart, and he is generally given credit for being the first to do this (1). Kergaradec in 1822 also heard fetal heart sounds, and described them in a classical monograph (2). De Paul claimed to have heard the fetal heart during the eleventh week of gestation in 1847, and suggested auscultation as an aid in determining the position of the fetus (2).

At the turn of the twentieth century, Hofbauer and Weiss attempted to record intra-uterine fetal heart sounds. Beruti in 1923 was successful in making a few photographic recordings of such sounds (1). Phonograph disc records of fetal heart sounds had also been made by Lian, Goldbin, and Minot in 1938 (1). In 1930, Hyman (3) thoroughly reviewed the history of fetal phonocardiography, and used for his

studies a stethoscope, microphone, galvanometer, and a camera. With a case report in 1939, Burnham (4) included a substantial bibliography of the foreign literature, and in 1940 Lund (5) reported his work with a cardiograph, with which he could both hear and write his observations. Smith and Hervert (6) in 1940 also reviewed the literature, and for their own work used a stethograph developed by Bieering, Bone and Lockhart. They reported 52 positive recordings in 58 cases from five and one half months to term. Smith (1941) (7), Dressler and Moskowitz (1941) (8), Steer and Hertsch (1951) (9), and Gunn (1953) (1), have also added to our knowledge of the fetal heart through the use of phonocardiography.

While the phonocardiograph enabled these workers to study fetal cardiac physiology more extensively than heretofore, they were handicapped by the technical difficulties of recording minute mechanical vibrations with sensitive apparatus which not only recorded the fetal heart sounds, but any type of movement on the part of the patient, as well as extraneous skin noises and borborygymi. Another serious limitation of the phonocardiograph is its inability to detect the fetal heart sounds at the height of a uterine contraction, when changes in fetal heart rate may be significant.

Even so, many observers have used auscultatory methods, and have noted irregularities in the fetal heart rate. In

1930, Hyman (3) reported fetal irregularities in nine per cent of the cases studied, and divided these into three types: 1) arrhythmias due to change in resonance and in sound intensity, 2) interruptions in normal rhythm, and 3) gross irregularities which he considered significant and clinically important. Burnham (1939) (4) also heard arrhythmias, and stated that marked irregularity of the fetal heart was a bad prognostic sign. It was also his opinion that study of the fetal heart could lead to the prenatal diagnosis of heart disease. Lund (5) in 1940 stated that his chief criteria for fetal distress were cardiac rate and rhythm; and slowing of the fetal heart, rather than tachycardia, was prognostically significant. He concluded that a sudden change of 25 beats per minute in the rate, or a persistant rate below 100 to 110 beats per minute indicated fetal anoxia. In a later work (1943) (10), he stated that transient fetal tachycardia is normal, and reported tachycardia in 23.2 per cent of the cases studied. These cases were divided into two groups; those with a rate of over 160 per minute for less than twenty minutes (17.6 per cent of the total group), and those with similar findings for more than twenty minutes (5.6 per cent of the total). It was his opinion that patients in the latter group were the only ones in which tachycardia was significant, and that tachycardia is often due to fetal movement, forceps

application, pressure on the fetal head, contractions, and stimulation. He used a phonocardiogram, and found that over 50 per cent of the tachycardias observed could be explained. He concluded that anoxia did not cause tachycardia in the fetus.

In 1948, Sankey (11) discussed the problem of congenital heart disease simulating fetal distress, and presented two cases in which slow fetal heart rates were heard by auscultation, and which turned out to have congenital heart disease. Abraham and Dyer (1949) (12) also felt that a transitory fetal tachycardia was not necessarily serious, and that a slow rate was of more clinical import. Thus we see that many workers found limited auscultatory investigation of the fetal heart promising.

While the major portion of investigations of the fetal heart had been confined to the audible range of the mechanical energy of the fetal heart, other workers were of the opinion that additional information might be gained from the study of the electrical fetal cardiac energy. Some of the earlier work in this area was directed at a basic understanding of this phenomenon in animal and human embryos.

Hoff, Kramer, DuBois, and Patten (13) in 1939 studied chicken embryos, and found that at the 15 somite stage (33 to 36 hours), the first indication of cardiac electrical activity

appeared, and that by 48 hours, both P and QRS complexes were present. By the fourth day, an "adult" electrocardiogram pattern was present. Lindsley (1942) (14) studied human fetuses in utero with a three stage resistance-capacity coupled amplifier of the push-pull type, and a Westinghouse mirror oscillograph with silver electrodes. He obtained a positive fetal electrocardiogram from the mother's abdomen as early as the fifth month of gestation. Patten (1944) (15) states that, "An electrocardiogram of the adult pattern from embryonic hearts can be obtained before the SA conduction system becomes recognizable from microscopic studies, before accelerator and depressor nerves have reached the heart, and before the coronary circulation has been established." Arey (1946) (16) wrote that the human heart began to pump blood during the fourth week.

To further substantiate this basic work, many studied the fetal heart with electrocardiograms taken directly from the fetuses either at hysterotomy or at term just after birth. Krumbhaar (1916) (17) reported that the fetal electrocardiogram was a "simple upright monophasic curve"; but is not clear whether he actually studied the fetus in utero. He felt that by the sixth postpartum month the electrocardiogram was of the adult type. He does not describe his equipment. Easby (18) in 1934 recorded an electrocardiogram from

a four and one half month old fetus which was 21 centimeters long, using copper wire electrodes; and states that the electrocardiogram was adult in type. Heard, Burkley, and Schaeffer (1936) (19) studied eleven fetuses using standard limb and chest leads with a regular electrocardiograph and copper wire electrodes. Tracings were positive in ten fetuses, ranging in age from nine and one half to 25 weeks. They carefully analyzed electrocardiogram components, and concluded that the electrocardiograms had the same major appearance as the adult, but that no Q waves were present.

Marcel and Exchaquet (20) in 1938 recorded five fetal electrocardiograms with leads placed directly on the fetus. Vara and Niemineva (1951) (21) compared electrocardiograms taken from the mothers' abdomen and the uterus and obtained greater amplitudes from the uterine wall, along with P waves, from fetuses ranging from 11 to 19 weeks of age. Mann and Mayer (22) in 1942 obtained fetal electrocardiograms from the uterine wall.

While basic work has added a great deal to our knowledge of fetal electrocardiography, to be of widespread clinical value studies are necessarily confined to the anterior abdominal wall of the mother. The possible clinical applications have therefore been extensively investigated over the past 50 years.

Shortly after the development of the string galvanometer by Einthoven (1903), Cremer in 1906 recorded the first fetal electrocardiograms (23,24). This was taken with an abdomino-vaginal lead in the last month of pregnancy.

Further advances in fetal electrocardiography were limited by technical difficulties. Foa (1911) reported a positive tracing (23,24). Sachs in 1922 and Haynal and Kellner (1924) were unsuccessful in obtaining fetal electrocardiograms (23,24).

With the development of the vacuum tube and its use for electrical amplification, which permitted the recording of minute potential changes, a new impetus was given to fetal electrocardiography. In 1930, Maekawa and Toyoshima recorded an electrocardiogram on a fetus just before birth using abdominal electrodes, a valve amplifier, and a string galvanometer (23). Steffan and Strassman (1933) also obtained a fetal electrocardiogram using an improved string galvanometer (23,25). Strassmann, who was one of the pioneers in this field used a tension electrocardiograph with a "heart tone apparatus" which amplified "in accordance with the principle of a loudspeaker" (25). In 1936 (25) he was successful in obtaining a positive fetal tracing eight days before birth. This is the first report of such a nature in the English literature. He used standard leads in addition to ones to the back,

abdomen, and thigh; and indicated that factors which affected the recording were position, muscle tremor, and the fetal cardiac axis. It was his opinion that the fetal electrocardiogram would aid in the study of the effect of labor, drugs, congenital abnormalities, and anoxia on the fetus, and that multiple pregnancies might be discovered. He also envisioned the routine use of the fetal electrocardiograph during the last two months of pregnancy. In later papers (1938) (26,27), Strassmann stated that the equipment must be kept simple, and practical; and that interference would have to be eliminated in order to improve results. He used saline for electrode-skin contact, and five leads to the proximal areas of the arms and thighs. During the last two months of pregnancy, he reported 52 cases in which 87 per cent of the tracings were positive (75 per cent of which were positive in at least two of his five leads). If the presentation was vertex, during the last three weeks his percentage of positive tracings rose to 94. He stated that a negative deflection was obtained with a vertex, while the breech presentation yielded positively deflected fetal electrocardiograms. Fetal electrocardiograms were obtained in 92 per cent of the cases of vertex presentation, while this figure dropped to 64 per cent with breech, because the positively deflected fetal electrocardiograms obtained with breech presentation were often

hidden by the maternal complex. His tracings showed only very small R waves. At that time, he felt that it was useless to attempt to obtain fetal electrocardiograms before the last trimester, and suggested using this equipment during labor.

Bell's outstanding paper in 1938 (28) reported the use of a balanced input amplifier and a standard electrocardiograph machine. To reduce baseline movement, he used small coupling condensers. For electrodes, metal discs were wetted with saline, and best results were obtained with leads from the fundus and symphysis. He was unable to record a fetal electrocardiogram in a four months pregnancy, but in 33 cases within two months of term, he was successful in one third, had questionable tracings in another third, and negative tracings in the final third. In the successful cases, deflections of several millimeters were obtained. The size of the fetal potential, the thickness of the abdominal wall, and the amount of amniotic fluid were thought to be factors of importance.

Bernstein (1940) (29), in reporting a case of gastroschisis, used the equipment designed by Mann, and recorded fetal electrocardiograms from the mother 42 to six days before birth.

Goodyer, Geiger, and Monroe in 1941 and 1942 (30-33) in a series of papers presenting work done at Yale used a single stage resistance-coupled amplifier with a portable electrocardiograph. Series condensers were inserted to stabilize the baseline and damp respiration potentials. Disc electrodes with jelly were used, and good results were most frequently obtained with epigastric-pubic symphysis leads. However, RUQ-LLQ and RLQ-LUQ electrode configurations should also be used. The fetal output was amplified 20 times, and fetal deflections of ten to fourteen millimeters equivalent to 70 microvolts obtained. One hundred eighty one electrocardiograms were attempted on 154 cases; 87 per cent were positive. The earliest was of 17 weeks duration, and best results were obtained during the tenth lunar month, when they were successful in 100 per cent.

They concluded that there was no decline in the fetal heart rate as the pregnancy progressed, that sex could not be correlated with rate, that there was no relationship between fetal age and the amplitude of the fetal electrocardiogram, and that it was no more difficult to obtain tracings in fat than in thin women. They were the first workers to attempt to obtain fetal electrocardiograms during labor, and recorded 18 cases. But these recordings were taken "between labor pains after engagement of the head and the beginning of

cervical dilatation", and therefore their conclusion that there was no change in the fetal heart rate during labor is open to some doubt. Apart from the study of fetal cardiac rate and rhythm, these workers felt that fetal electrocardiography was useful for the diagnosis of multiple pregnancy. Technical factors they considered were the shielding of the fetus by the membranes and the amniotic fluid, the axis of the heart, the thickness of the body wall, muscle tremor, amplifier noise, external interference, and fetal movement. They felt an electroencephalograph offered no advantages, and as others before them, pointed out the many uses of such a study.

Dressler and Moskowitz (1941) (8) studied the fetal heart sounds and fetal electrocardiograms simultaneously. They reported 40 cases within 67 days of birth, in which positive heart sounds were recorded in 100 per cent, and fetal electrocardiograms in 80 per cent. Sondergaard (1942) was successful in 15 of 17 cases using abdominal leads, and Borter (1943) was successful in 100 per cent of his cases taken during the last month of pregnancy (34). Putz and Ulrich used abdominal leads and recorded a fetal electrocardiogram in a six months gestation (21,34).

Mann and Bernstein (1941) (23) used standard electrodes with paste, an amplifier, and an electrocardiograph with a

sensitivity of two to five centimeters per millivolt. They compared proximal extremity leads with abdominal leads and concluded that abdominal leads were superior. In 76 records obtained from 40 cases, they had positive tracings in 77 per cent, the earliest being obtained in the fourth month; all of the tracings during the ninth month were positive. Mann and Mayer (22,35,36) in 1942 reported having obtained a fetal electrocardiogram six days prepartum. The sensitivity of their equipment, which consisted of a Sanborn Cardiette and German silver electrodes was six centimeters per millivolt.

Ward and Kennedy (1942) (20) were of the opinion that the major problem was the small fetal potential and used a three channel electroencephalograph with a balanced amplifier. The time constant was short enough to smooth out the baseline. Like many of the previous workers, they used flat electrodes and jelly, and abdominal leads. The earliest positive tracing was secured during the sixteenth week, and 67 per cent of 46 records were positive. After the sixteenth week, the per cent rose to 82 per cent, and all of the cases in the ninth month were positive. Deflections equivalent to 30 microvolts were recorded.

Bernstein and Mann (1942) (37), using a Sanborn Cardiette and amplifiers with a sensitivity of six centimeters per millivolt, abdominal leads, and standard electrodes and paste,

reported 153 records from 100 patients. Unfortunately, records of all premature and abnormal labors, and Caesarian sections were excluded from their report. Seventy six per cent of their tracings were positive; this figure rose to 96 per cent in the last two months. A drop in the percentage of positive tracings in the seventh and eighth months, which also had been observed by Goodyer, Geiger, and Monroe, was noted. These authors doubted if increased amniotic fluid could account for this. With obese patients they were less successful in obtaining recordings. Goodyer, Geiger and Monroe did not find any such difference. (32).

Lindsley (1942) (14) used with success a three stage resistance-capacity coupled push-pull type amplifier and a Westinghouse mirror oscillograph with silver disc electrodes placed on the abdomen. He claimed that if both electrodes were placed in the midline, the maternal component would be eliminated from the recording. Paley and Krell (1944) (38) reported 22 cases using a string galvanometer with a sensitivity of two to three centimeters per millivolt. The best lead was from epigastrium to symphysis, and limb leads were not as good. Fifty three per cent of their records were positive, with a lower percentage during the seventh and eighth months. It was their opinion that improved technique would permit the use of the fetal electrocardiogram to

determine viability, pseudocyesis, multiple pregnancy, fetal arrhythmias, fetal distress, and congenital heart lesions.

Plant and Steven (1945) (39) reported the use of a Cardiette with an amplifier yielding an increment of 2.5, and abdominal leads.

Vara and Halminen (1946) (34), who have made significant contributions in this field, greatly improved their records by increasing the paper speed. To provide the necessary increase in sensitivity, they used a preamplifier which increased the gain of a standard electrocardiograph by a factor of 20. The majority of the 30 positive cases reported were done with abdominal leads and plate electrodes. In one instance, a cervical electrode was used in a first trimester gestation. Their positive tracing at twelve weeks gestation is the earliest reported in the literature. In 1951, (40) they reported 92 cases in which they had obtained positive fetal electrocardiograms. There were no false positive tracings in their entire series.

Blondheim (1947) (41,42) reported the use of an electroencephalograph machine, standard plate electrodes with jelly, abdominal leads, and a four channel push-pull amplifier. He felt that the fetal electrocardiogram could be seen best when superimposed on the maternal configuration (as opposed to most other investigators). Eighty two per cent of 28

tracings from 25 patients were positive; and fetal deflections of eight millimeters equivalent to seven microvolts were noted. He agreed with Goodyer, Geiger, and Monroe that both midline and oblique abdominal leads were necessary, and like them, also noted a decrease in positive results during the sixth and seventh months.

Of the factors affecting the fetal heart rate, he stated that asphyxia increased the rate, and uterine contractions and increased intra-cranial pressure decreased it.

Pfister and Plice (1950) (43) advocated the use of large electrodes made from tin cans, paste, abdominal leads, and a vacuum tube amplifier; their equipment had a sensitivity of 45 millimeters per millivolt. They were successful in recording fetal electrocardiograms in 36 consecutive cases near term, and believed that large electrodes were very important; they claimed to be able to use the opposite ends of their long epigastric electrode in conjunction with the symphysial lead to give two distinct electrocardiographic configurations.

Smyth (1953) (44), in an interesting paper, pointed out that fetal distress would have to be recognized earlier if the stillbirth rate was to be lowered, and therefore that continuous automatic recording was necessary. In over 100 cases, he reported only two negative results (in both cases

the child was dead), using a direct writing electrocardiograph, a balanced preamplifier, silver disc electrodes and saline, and midline abdominal leads. He described the use of a grounded metal braid belt around the patient's waist, between the abdominal electrodes and the maternal heart, to make the abdominal skin isoelectric to the maternal heart, thereby eliminating the maternal electrocardiogram from the tracings. The "iso-electric" belt was successful in only 20 per cent of the patients, and even then it merely produced a fetal complex larger than the maternal; the latter was not completely eliminated. An integrator for the fetal heart rate and a neon light which flashed with fetal heart beats were also described. The ratemeter was accurate only when the fetal impulses were the largest components recorded. There was no indication if any of the records were taken during labor, or at what point during the pregnancy the tracings were made, although one positive tracing at 20 weeks is mentioned. He discarded the idea of eliminating the maternal electrocardiogram by anti-phase cancellation because such a system would be cumbersome. Interference from voluntary muscle was reduced by limiting the high frequency cut-off of the amplifier to 40 cycles per second.

In 1954, Southern (24) carefully reviewed the progress of fetal electrocardiography and reported that he had obtained

98 per cent positive tracings in 110 term patients. In 80 selected cases, starting at the fifteenth week of gestation, positive results were recorded in 85.8 per cent, the earliest positive recording occurring at the seventeenth week. Welsh suction electrodes and jelly, epigastric-symphysial leads, a standard electrocardiograph, and a single stage resistance-coupled valve preamplifier were used.

In a more recent study (1957) (45) he reported his experience with equipment which was made up of vector amplifiers, lead selector system, Sanborn Twin-beam Cardiette, and monitoring oscilloscope. The total sensitivity of the system was 25 centimeters per millivolt. The configuration of the normal fetal electrocardiogram was described and the duration of and time intervals between various portions of the electrocardiogram given. However, no tracings of normal fetal electrocardiograms are shown. In fetal anoxia, he reported fetal electrocardiogram configuration changes and was of the opinion that a fetal heart rate between contractions of less than 100 beats per minute was indicative of distress. No statement is made as to how long the patients were studied, and whether recordings had been made at the height of a contraction.

Davis and Meares (1954) (46,47) reported the use of a Grass Model III electroencephalograph with a sensitivity of

40 microvolts per centimeter. They used abdominal leads and three different types of electrodes; solder pellets, seven millimeters in diameter; a metal sphere, 13 millimeters in diameter for a cervical lead; and standard cuplike electrodes. In 17 patients ranging from 17 weeks gestation to term, they were successful in 29 of 32 tracings. Their paper included a "prototype" of a normal fetal electrocardiogram, formulated from averaging and superimposing normal fetal electrocardiograms obtained from many patients.

Bernstine and Borkowski (48) in a review article in 1955 reported positive tracings in 50 cases.

While the contributions of the many workers in the study of fetal electrocardiography has added greatly to our knowledge, its real clinical value remains to be determined.

SURVEY

SURVEY

Even though the first fetal electrocardiogram was recorded over 50 years ago, the probable significance of fetal electrocardiography is as yet poorly understood. A number of conflicting opinions concerning techniques are recorded in the literature and while its clinical value is suggested by many workers, there is not a great deal of evidence to support such a view.

With the recent advances in electronic instrumentation, and their probable application to medical problems, we are in a good position to review and evaluate the technical shortcomings of prior instrumentation systems, apply possible remedies, and thereby more truly assess the role of fetal electrocardiography in the study of "fetal distress" and in the detection of fetal viability in the second and third trimesters of pregnancy.

The clinical problem of perinatal mortality is of large dimension and has not been lessened despite many attempts to do so. Although maternal mortality has been progressively reduced, the reduction of stillbirths and neonatal deaths has been only a small fraction of the gains made in maternal mortality. The maternal mortality rate in 1929 was 69.5 per 10,000 live births; today it is five and three tenths per

10,000 live births. This great reduction in mortality has not been matched by improvement in fetal salvage. At present, infant mortality is 266 per 10,000 live births, and four per cent of reported pregnancies over twenty weeks end in stillborn or neonatal deaths. Thirty-two per cent of neonatal deaths and 59 per cent of infant deaths are not associated with prematurity (49).

Bieber (50) reported that 83 per cent of the cases of premature separation of the placenta occur during labor, and that this condition results in a stillbirth rate of 40 per cent. Von Winkel stated that a fetal heart rate above 160 beats per minute or below 100 per minute should be considered distress; Stander agreed with these conclusions (51). Fitzgerald and McFarlane (51) have set up criteria for fetal distress as manifested by the fetal heart rate and rhythm; they found a six and one half per cent incidence of fetal distress, and felt that the normal fetal heart rate was between 120 and 160 per minute. They recognized that variation of rate with uterine contractions would constitute a very valuable sign, but were unable to carry out these observations. They noted that 37 per cent of all stillbirths occurred during labor, and that a policy of non-intervention gave a mortality in these cases of 25 per cent while Caesarian section or forceps delivery reduced stillbirths to 13 per cent.

Burnham (4), Tarnower (52), Abraham and Dyer (12) and Lund (5,10) have also considered the fetal heart rate in their studies, but currently there is no agreement as to what constitutes an abnormal fetal rate or rhythm during labor.

A continuing problem of this magnitude suggests a lack of basic understanding of "fetal distress" and indicates an acute need for a clear definition of this important condition.

It is the purpose of this thesis to report the application of modern electronic instrumentation to the study of fetal electrocardiography, and to give the results of a limited clinical trial of these newer techniques. The fetal electrocardiogram has been used to determine the normal range of the fetal heart rate during labor, to study the effect of uterine contractions on the fetus, and to evaluate "fetal distress". In addition, the equipment has been used for diagnosis in cases where the fetal heart has not been heard, and in situations where evidence of fetal life or death was an important consideration in therapy and management. An attempt will also be made to elucidate conflicting reports present in the literature whether they be of a technical or clinical nature.

BASIC CONSIDERATIONS

BASIC CONSIDERATIONS

It is probable that many unanswered questions concerning fetal distress are due to the failure of the medical researcher to fully appreciate the limitation of the apparatus which he is using. The exploration of this problem by investigators who are skilled in electronic as well as biological techniques and the use of equipment adequate for all phases of this type of study may provide important new data.

The majority of the equipment which has been used for the study of fetal electrocardiography has been slightly modified commercial equipment primarily designed for clinical adult electrocardiography.

The use in research of clinical equipment designed for another purpose may so limit the acquired data that its significance and validity may be seriously impaired. It is mandatory that any instrumentation system be of sufficient range to accommodate any frequencies likely to be met and to be relatively free from artifacts due to electrical interferences or intrinsic noise. For maximum clinical value the equipment must be simple to operate and not cumbersome.

Technical

Electrodes. From the electronic standpoint an electrode is an integral and very important part of the pre-amplifier stage, and its characteristics may influence to a large extent

the character of the final tracing recorded. In spite of its significant role in a recording system, electrodes used for the study of fetal electrocardiography have received only minor attention and most workers have used standard adult electrocardiograph electrodes and electrode jelly.

For the continuous study of patients in labor, the electrode must be comfortable, readily and firmly affixed to the abdominal wall, and cause the minimum number of artifacts whenever the patient moves. Electrically they must be capable of picking up the fetal electrocardiographic signal and transmitting it to the preamplifier without distortion or addition of interfering signals such as polarizing potentials. The skin-electrode resistance must be kept at a low, and relatively constant level. Spurious potentials due to skin-electrode frictional changes should be minimized by preventing the electrode from making direct contact with the skin and providing instead a low resistance fluid conductor as a bridge between them.

Amplifiers and Interfering Signals. As recorded from the anterior abdominal wall, the fetal QRS complex is about 25 microvolts in amplitude. In order to provide an adequate input signal for the average oscillograph, high gain preamplifiers are necessary. Besides being sensitive, these amplifiers

must be stable, have low inherent noise levels, and be capable of rejecting unwanted electrical signals. While adequate sensitivity is readily obtainable with vacuum tube amplifiers, unless they are carefully designed, the intrinsic noise levels may be of such magnitude that fetal P and T waves are lost completely.

Faithful reproduction of the fetal electrocardiogram configuration is contingent on a satisfactory frequency band pass characteristic and it is therefore very important to have this wide enough to pass any frequencies that may be met.

Apart from the interfering noises arising from outside sources or within the amplifiers themselves, the maternal electrocardiogram is detected on the abdominal wall together with the fetal electrocardiogram. Since these heart rates are independent of each other, the maternal electrocardiogram may be occasionally coincident with the fetal electrocardiogram, and completely mask or distort it. Lindsley was of the opinion that the maternal electrocardiogram could be eliminated by midline electrode placement, while Smyth sought to achieve the same end with an "iso-electric belt". In practice, neither of these methods consistently achieved the desired result.

Recording Oscillographs. The recording oscillograph should be able to reproduce without distortion the signals fed to it by the amplifying stages. It should, therefore, be of adequate sensitivity, capable of rejecting interfering electrical signals, and free from intrinsic noise. All these requirements are met relatively easily. The most difficult criterion is to produce an adequate band pass width, since most direct writing oscillographs cut off sharply at about 100 cycles per second. Photographic type oscillographs using light beam galvanometers have a better high frequency response but are very inconvenient if long records are to be processed. In the main, the vast number of studies of fetal electrocardiography have employed either of these oscillographs.

This requirement could be fulfilled by a direct writing oscillograph that has a high frequency range to about 500 cycles per second and thereby permits recording of higher order harmonics which are now lost in low frequency recording systems.

Oscilloscopes. A monitoring oscilloscope is useful to check instantaneously the phenomenon under study, and to provide a means of selecting data for permanent recording. The majority of commercial oscilloscopes are adequate for this purpose. A two beam oscilloscope is better than a single beam, since it allows simultaneous observation of two kinds of data.

Data Acquisition and Reduction. If fetal electrocardiography is used for short time studies, such as the diagnosis of fetal viability or configuration studies, an adequate preamplifier and recording oscillograph are all that are necessary. However, if the fetal electrocardiogram is to be used to determine fetal heart rate and rhythm throughout the course of labor where a single study may be of ten to 15 hours duration, some type of semi-automatic equipment must be used. In a single labor there may be 100,000 to 150,000 fetal electrocardiogram time intervals, and 100 to 150 uterine contractions. If fetal heart rate and rhythm are to be correlated with the strength of uterine contractions, the raw data has to be collected in a manner which allows semi-automatic data reduction, if a maximum amount of data is to be recovered with minimum effort. Unless a statistically significant number of "normal" patients are studied throughout labor, the diagnosis of "fetal distress" in terms of fetal cardiac rate and rhythm will remain tenuous.

Clinical

Electrode Placement. From the study of adult electrocardiography, it is evident that electrode positioning has a profound effect on the configuration of the electrocardiogram complex. With the fetus, it is not always possible to determine accurately the relationship of electrodes to the fetal

cardiac position and until an extensive investigation of the effect of electrode positioning on the fetal electrocardiogram complex is made, the significance of fetal electrocardiogram configurations will be in doubt.

Up to the present time, most studies have been concerned with the detection of the fetal QRS complex and its polarity. For this work, most investigators feel that the midline epigastric-symphysial lead is the single best lead, but that frequently other electrode positions are necessary to detect the fetal electrocardiogram. Rectal, vaginal, and cervical electrodes have been occasionally used, and usually discarded because of the inability to firmly fix these to the tissues and thereby causing tissue-electrode "noise".

There remains, therefore, a need for a careful evaluation of all electrode positions.

Polarity of Fetal Complexes. It is the opinion of some workers (Bell (28), Strassmann (25), Goodyer, Geiger, and Monroe (32), Southern (24), Pfister and Plice (43), Dressler and Moskowitz (8)) that the polarity of the fetal QRS is helpful in distinguishing vertex and breech presentations. In a vertex presentation, it is thought that the fetal deflection is negative (discordant to the maternal complex); while in a breech presentation, the fetal deflection

is positive (concordant with the maternal complex). Vara and Halminen (34), Sondergaard (34), Katz (53), and Blondheim (41) disagree. While this is generally true (because of the electrode positions most workers have used), the assumption does not necessarily hold for all cases. In the adult it is possible to reverse the polarity of the QRS complex by simply changing the electrode position with respect to the mean QRS vector. It is likely, therefore, that electrode positioning is of importance in fetal electrocardiogram polarity studies.

Maternal Habitus. There has been little previous mention of the effect of maternal habitus on the ability to recover the fetal electrocardiogram. Goodyer, Geiger and Monroe (32) and Blondheim (41) believe that habitus is insignificant; Bernstein and Mann (37) feel that it is important. Pfister and Plice (43), Bernstein and Mann (37), and Paley and Krell (38) feel that amniotic fluid has no effect on the fetal electrocardiogram while Bell (28) disagrees with that conclusion.

Further study of this aspect of the problem would lead to more effectively designed equipment and better placement of electrodes, and thereby eventually to more significant data.

In connection with this, Bernstein and Mann (37), Paley and Krell (38), and Blondheim (41) have noted a decline in the percentage of positive tracings in the seventh and eighth months of gestation. The reason for this finding remains obscure.

MATERIALS AND METHODS

MATERIALS AND METHODS

Diagnosis of Fetal Viability and Related Study

Electrodes. For short term studies of the fetal electrocardiogram, the standard Welsh suction electrode has been used with some type of conventional electrode jelly as a conductor. If the patient is fairly well relaxed, and body movement is kept to a minimum, these electrodes are quite satisfactory for periods of study up to an hour, and therefore are adequate for diagnostic studies. If they are kept on the abdominal wall for longer periods, they may cause mild ecchymosis and occasional blisters. Long periods of recording will require a type of electrode similar to one now being used for studies of patients throughout labor.

Preamplifier. In order to provide a signal large enough for standard direct writing electrocardiographic machines, some type of low noise level preamplifier must be used for the fetal electrocardiogram. After trying various preamplifiers, the Tektronix Model 122 low level battery operated preamplifier was found to be the most suitable. With selection of the tubes for the first stage, and careful balancing of the input stages, the intrinsic noise levels are quite low, and outside electrical interference is kept to a minimum.

Two different systems have been used for the detection of the fetal electrocardiogram. In the first instance, no attempt is made to remove the maternal electrocardiogram so this always appears on the tracing greater in amplitude than the fetal electrocardiogram. For this type of study, one preamplifier is used and electrode positioning similar to those feeding the lowermost preamplifier in Figure 1 is used. The output of this amplifier is connected to the lower channel of a direct writing electrocardiograph machine and a record similar to that shown in Figure 2 obtained.

The other system uses the additional amplifiers in Figure 1 and is used for the detection of the fetal electrocardiogram in order to cancel or attenuate the maternal electrocardiogram so that the fetal electrocardiogram will be greater in amplitude and therefore more readily seen. The separation of the maternal and fetal electrocardiograms is done by in-phase cancellation of the maternal complex in a differential amplifier.

One input channel is connected to electrodes from the lower abdomen of the pregnant patient where both maternal and fetal electrocardiograms are present. The other input channel is connected to two electrodes on the upper abdomen where the maternal electrocardiogram alone is present. This maternal electrocardiogram should be of the same configuration and

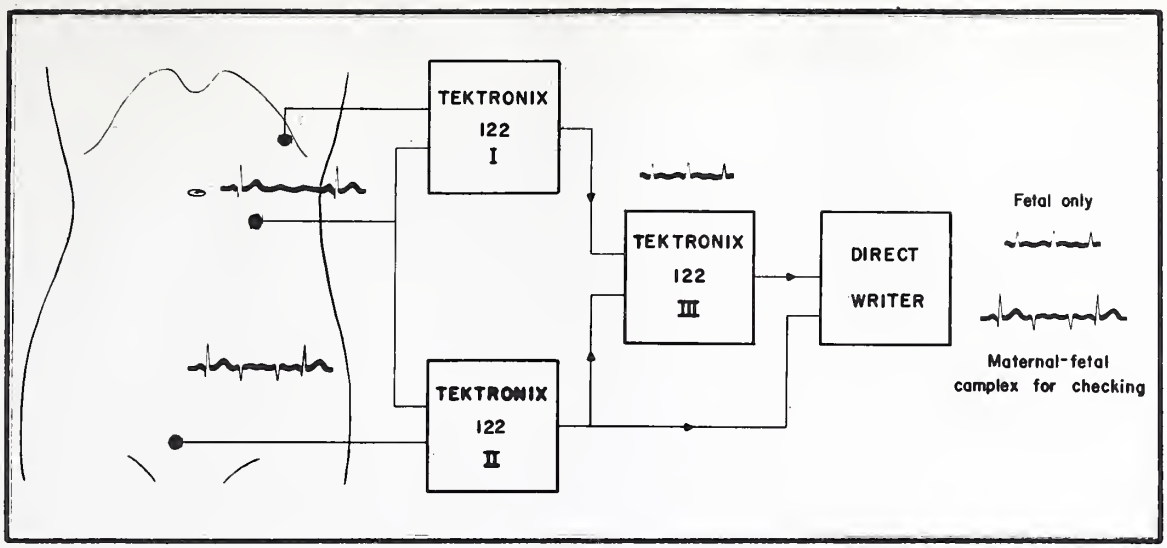

Figure 1 Electrode and preamplifier connections for the detection of the fetal electrocardiogram and fetal heart rate studies. For cancellation or attenuation of the maternal electrocardiogram all three Tektronix 122 preamplifiers are used; if a composite maternal fetal record is required number "II" preamplifier and its associated electrodes is used.

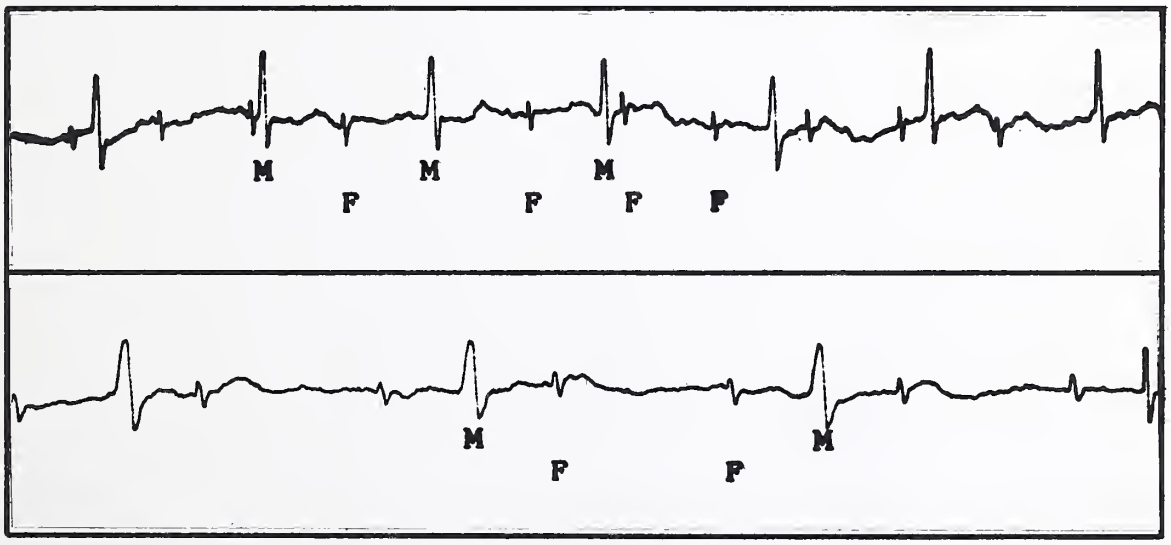

Figure 2 Fetal electrocardiogram recorded in between contractions from a patient in labor. Top channel 25 mms./sec. Lower channel at 50 mms./sec.

amplitude as the lower one since it is used for cancellation. Discrimination against outside electrical interference is achieved by using differential amplifiers ahead of the cancelling amplifier. Figure 3 (page 37), shows the results of this equipment and demonstrates the use of a decade counter. Figure 5 (page 38) illustrates the progressive steps in data processing.

Electrocardiograph. Much of the early exploratory studies were done with a Sanborn Twin-beam Cardiette, which is a two-channel electrocardiograph capable of photographically recording frequencies up to 300 cycles per second. This advantage over the usual direct writing electrocardiograph is somewhat negated by the inconvenience of not immediately having a visual record and the need to process considerable lengths of photographic paper.

The majority of the tracings have been recorded with a two channel direct writing Elema electrocardiograph. This instrument uses a jet-type of recording unit so that ink is sprayed onto the paper and as a result there is no friction between the writing medium and the paper. Frequencies up to 900 cycles per second may be recorded with this machine. The paper speed ranges from 0.25 centimeters per second to ten centimeters per second. These are more than adequate for

fetal electrocardiogram studies. The ability of the machine to record higher frequencies allows a more accurate appraisal of fetal electrocardiogram configurations.

Oscilloscope. A two channel oscilloscope is used at all times to provide a continuous visual data monitor. Such a monitor is not absolutely necessary if a direct writing electrocardiograph is being used but it aids in more selective recording. For this work, two channel electronic switches have been used with single beam oscilloscopes. These switches are quite satisfactory providing they have a good low frequency response and are not subject to cross-over from one channel to the other.

Fetal Heart Rate and Rhythm Studies

Electrodes. The fixing of electrodes to a moving patient for long periods of time imposes particular problems. After many attempts to provide a satisfactory electrode for this purpose, it was found that one centimeter diameter pure silver sheet electrodes, specially fabricated and inserted into a two centimeter diameter shallow rubber cup proved quite satisfactory. The junction to the connecting wire was made external to the cup, and the electrode held in such a position that it can not make direct contact with the patient's skin. Electrical contact is made with a small piece of cotton

thoroughly moistened with saturated sodium chloride. The electrode is held in place with a small circle of adhesive tape or collodian. A small hold in the top of the rubber cup permits wetting the electrode from time to time. The connecting wires are very light and are plastic covered. Noises due to patient movement are kept to a minimum because there is no direct skin-electrode contact and hence no frictional "noises" created.

Data Acquisition. To date only a small number of patients in labor have been studied. As far as possible, labor is followed from the time the patient reaches the labor floor until they are ready for delivery. Since this is usually many hours in length, many hundreds of feet of recording are obtained from a single labor. The equipment currently used is the same as that employed for fetal viability studies and has been previously illustrated in Figure 1 (page 32). Because of the massive amount of data to be acquired per labor, semi-automatic data acquisition and reduction systems are being planned.

Data Reduction. The data accumulated to the present time has been manually reduced by measuring the time intervals between individual fetal electrocardiogram impulses, converting them to frequency per minute, and then plotting these

against the duration of the uterine contractions. This is a time consuming and laborious procedure and is not suitable for extensive study of this problem. To expedite data reduction semi-automaticity must be instituted. A very preliminary step in more rapid data reduction is illustrated by the use of a decade counter as shown in Figure 3 and Figure 5, Tracing C, where each fetal electrocardiogram is represented by a negatively directed spike and every tenth impulse by a positively directed spike. The maternal electrocardiogram is not counted by the decade counter.

Semi-Automatic Data Reduction. Figure 4 is a block diagram of a semi-automatic data reduction system being developed. The unprocessed data will be recorded on magnetic tape all through the course of labor. At its completion, the tape will be sent to the data reduction laboratory where it will be reduced.

The two channel direct writing oscillograph will plot the instantaneous fetal heart rate against the amplitude of the uterine contraction and the fetal heart meter will provide an instantaneous numerical rate. The servo system controls the recording speed of the direct writing oscillograph, and if the fetal heart rate is within "normal" limits a compact record will be provided. If this becomes either

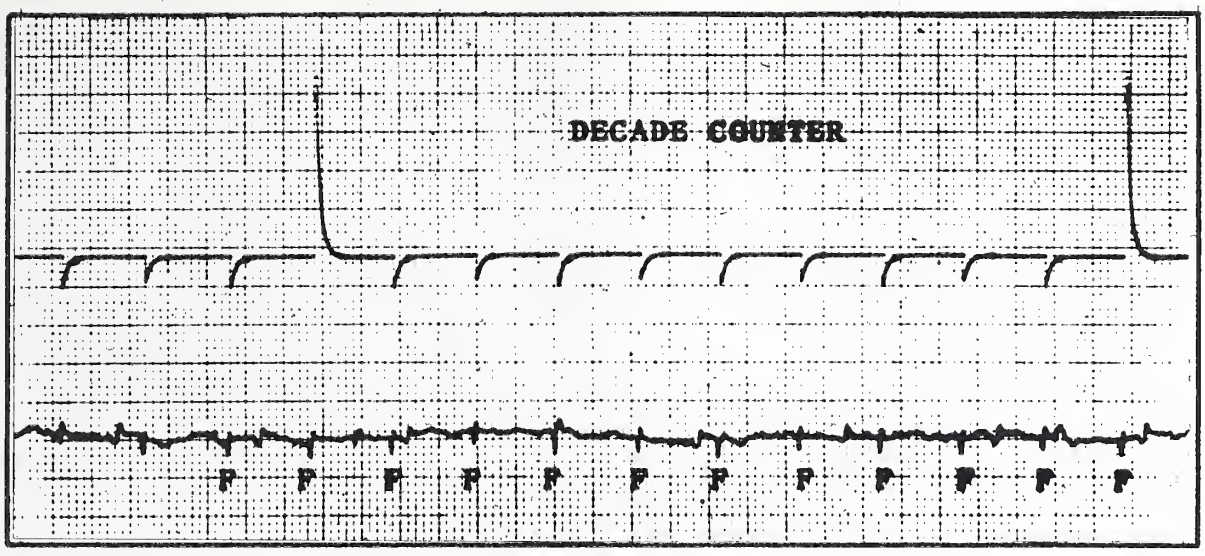

Figure 3 Maternal and fetal electrocardiograms showing cancelling of maternal electrocardiogram and use of decade counter.

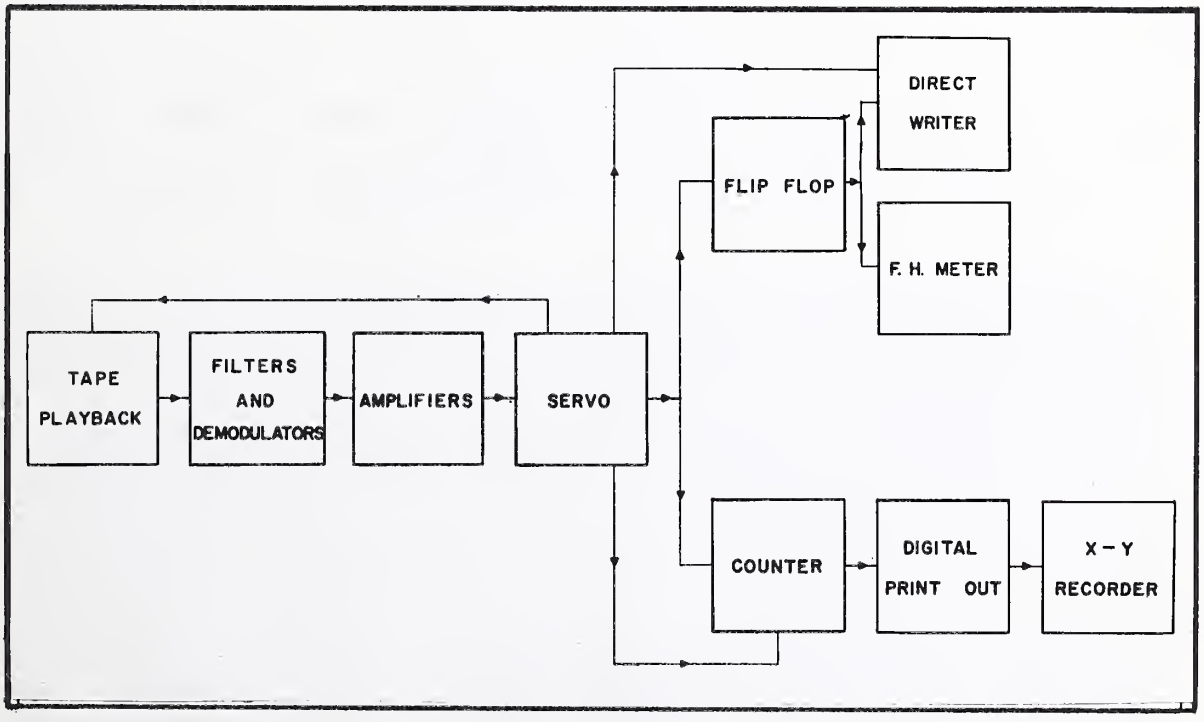

Figure 4 Block diagram of semi-automatic data reduction system now being designed. The servo system controls the recording speed of the direct writing oscillograph and the operation of the electronic counter, digital print out and X-Y recorder.

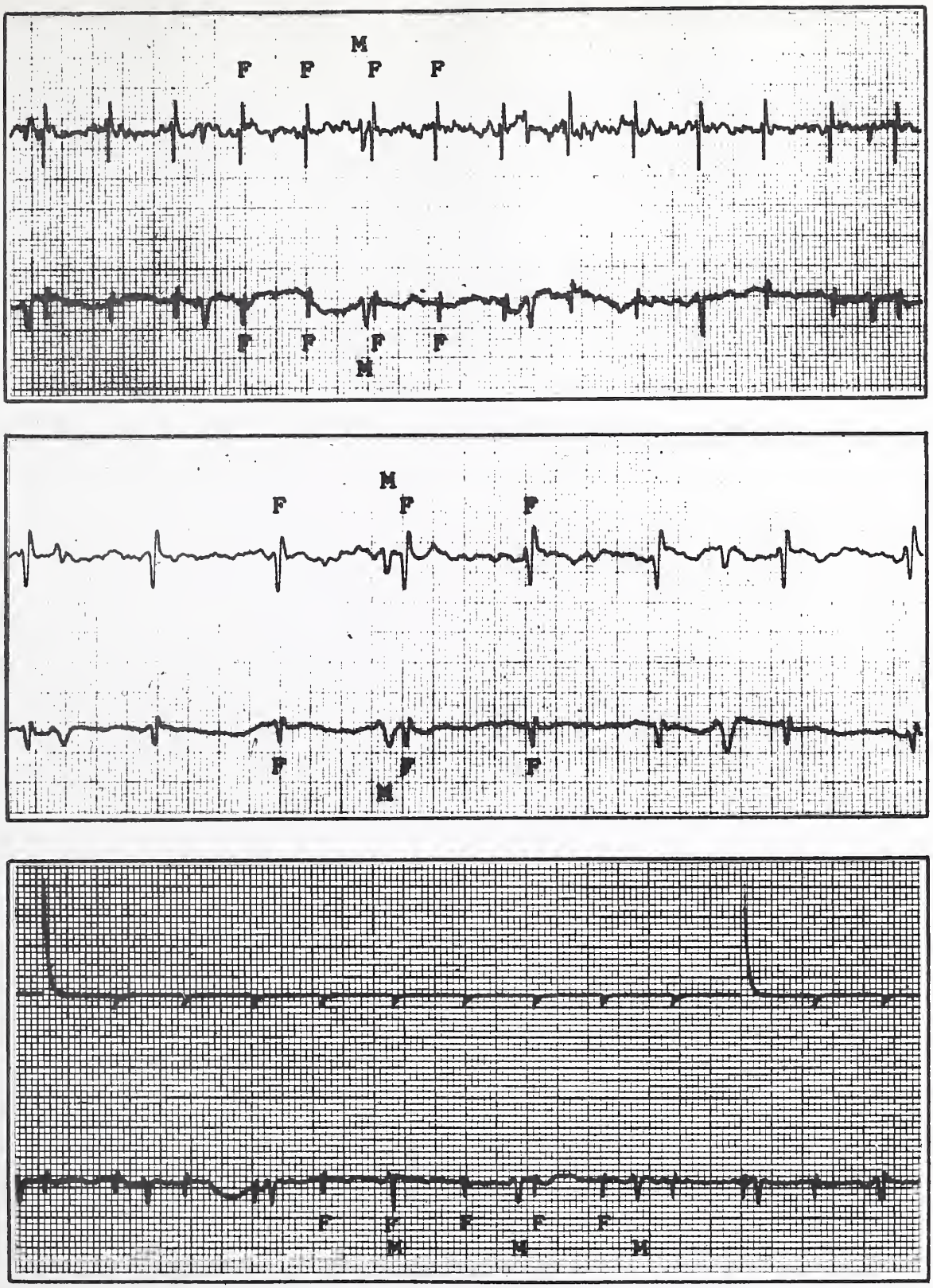

Figure 5 Tracings taken from the same patient to show stages in data processing.

A 56-1009 Upper channel: Attenuated maternal complex
Lower channel: Unprocessed data

B 56-1009 Same as tracing A. Paper speed 50 mms./sec.

C 56-1009 Decade counter recording only fetal pulses

too slow or too fast, the recording speed will be increased and a more detailed record provided. At the same time the electronic counter, digital print out, and X-Y recorder will also be turned on. In this way, any abnormal sections of the labor will be recorded in detail, thereby giving much more information than the compact "normal" areas.

RESULTS

RESULTS

The primary effort in this study has been directed towards the development of adequate instrumentation (see Materials and Methods) for the use of fetal electrocardiography as a tool for the diagnosis of fetal viability and for the evaluation of the fetal heart rate during labor. Although clinical studies to date have been somewhat limited, it is already apparent that the use of better instrumentation will aid in clinical management of the pregnant patient and will frequently provide information not made available by current diagnostic techniques. The fetal heart is often not heard by the usual auscultatory methods for various reasons: early gestation (less than five months gestation), obesity, polyhydramnios, and posterior presentations. Any factors which tend to displace the fetal heart away from the maternal abdominal wall make it difficult and often impossible to hear the fetal heart. During labor, because of patient movement and muscle noise, fetal heart sounds may be masked. It is in such situations that the fetal electrocardiogram is very useful. To illustrate some of the probable uses of this equipment, a number of clinical situations will be presented and the role of the fetal electrocardiogram demonstrated.

Fetal Viability. By and large the greatest number of requests for fetal electrocardiography have come from physicians who were unable to determine the status of the fetus by auscultatory methods or by x-ray studies. Auscultation is frequently difficult because of the above mentioned reasons.

From the clinical standpoint it is frequently very important to know the status of the fetus. This is particularly true in the second and third trimester bleeding problems, in toxemias of pregnancy especially if polyhydramnios is present, and in hypertensive cardiovascular disease. The presence or absence of fetal life often has a profound effect on the immediate handling of the situation.

In the following typical cases, the status of the infant was not definitely known, prior to the use of fetal electrocardiography, in spite of repeated attempts to determine it.

The first five cases were patients in whom no fetal electrocardiogram could be identified and who subsequently delivered dead fetuses. To date, regardless of marked obesity or polyhydramnios, there have been no false negative results beyond 20 weeks of gestation.

56-1006 (Figure 6A, Tracing A, Page 44). This patient's gestation was of 28 weeks duration and she had been

bleeding for two days without cramping. An x-ray taken two weeks earlier was interpreted as showing a normally developing fetus. At the time of admission to the hospital, the fetal heart could not be heard. Electrodes placed on the mother's abdomen failed to pick up the fetal electrocardiogram. Ten days later, following induced labor, a macerated stillborn fetus was delivered.

56-1005 (Figure 6A, Tracing B, Page 44). This obese 34 weeks pregnant patient had pre-eclampsia and pyelonephritis. The fetal heart was not heard on admission and because of the marked obesity a definitive diagnosis of fetal death could not be made.

The fetal electrocardiogram was not recorded, and eight days later a 1219 gram macerated stillborn infant was spontaneously delivered.

57-0208 (Figure 6A, Tracing C, Page 44). The patient was a 31 weeks gestation in whom the physician could not hear a fetal heart during a routine office check-up during a presumably normal pregnancy. No fetal electrocardiogram could be identified. Four weeks later a macerated stillborn weighing 1361 grams was delivered.

56-1102 (Figure 6B, Tracing D). This case was an 18 weeks pregnancy, and an x-ray showed a fetal skeleton, The fetal electrocardiogram was not found. A pregnancy test one week later was negative. The patient subsequently had a complete abortion at home.

57-0218 (Figure 6B, Tracing E). Fetal life in this patient had been detected five days previously. At the time of examination with the fetal electrocardiograph, no fetal electrocardiogram was detected. One week later, at the forty-second week of gestation, the patient spontaneously delivered a macerated 3048 gram stillborn infant.

The second group of five cases are typical of those instances in which the fetal heart is not heard on auscultation, yet a viable infant is present.

57-0221 (Figure 7A, Tracing A, Page 48). This patient was pregnant 41 weeks. On admission the fetal heart was noted to be normal by auscultation, but two hours later it could not be heard, even though numerous observers checked the patient. The possibility of fetal death was entertained but a normal fetal electrocardiogram was obtained. Both patient and physician were reassured and the following day a normal full term baby was delivered.

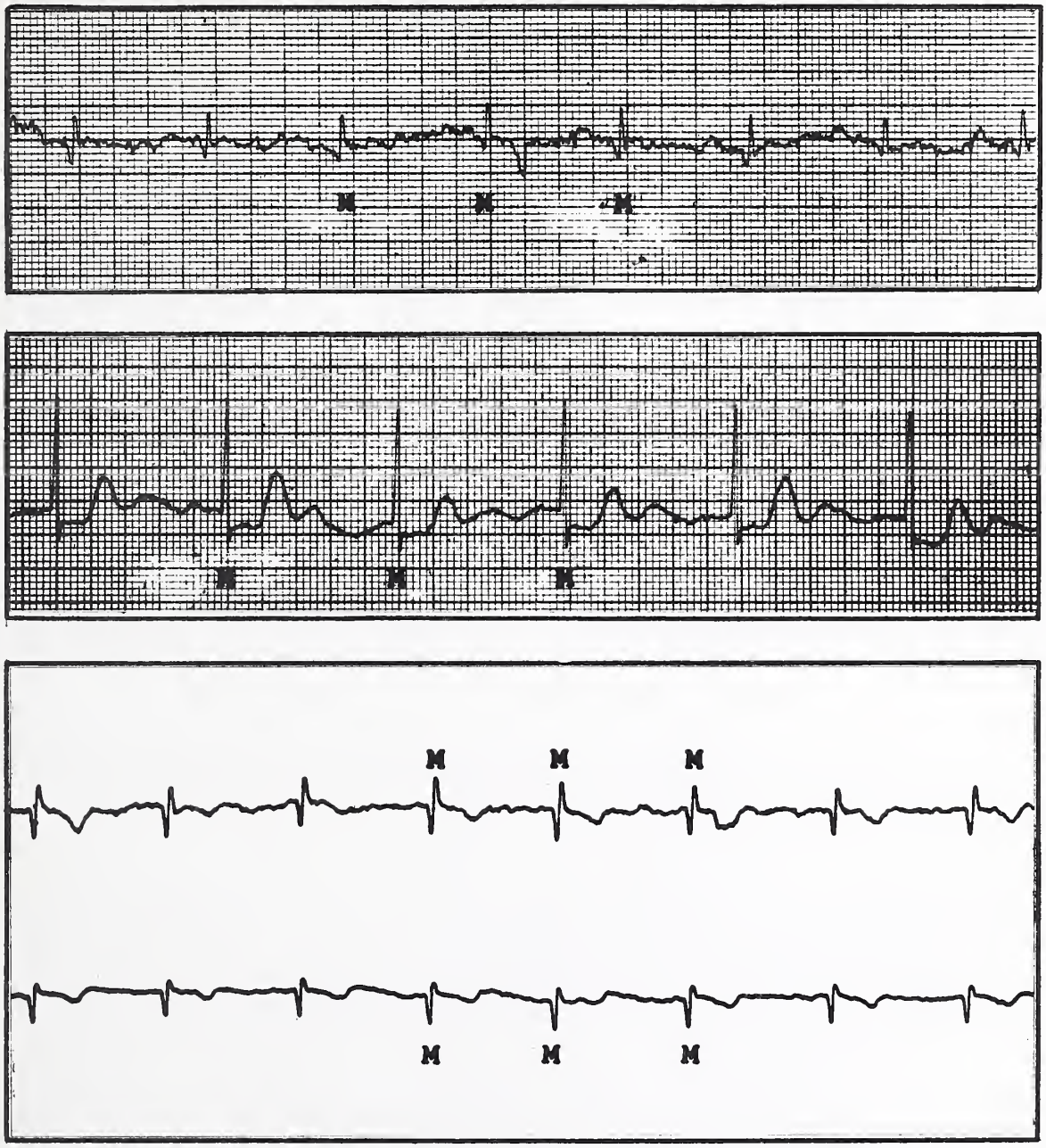

Figure 6A Tracings indicative of fetal death where other methods were inadequate for diagnosis

A 56-1006 28 weeks gestation
B 56-1005 34 weeks gestation
C 57-0208 31 weeks gestation

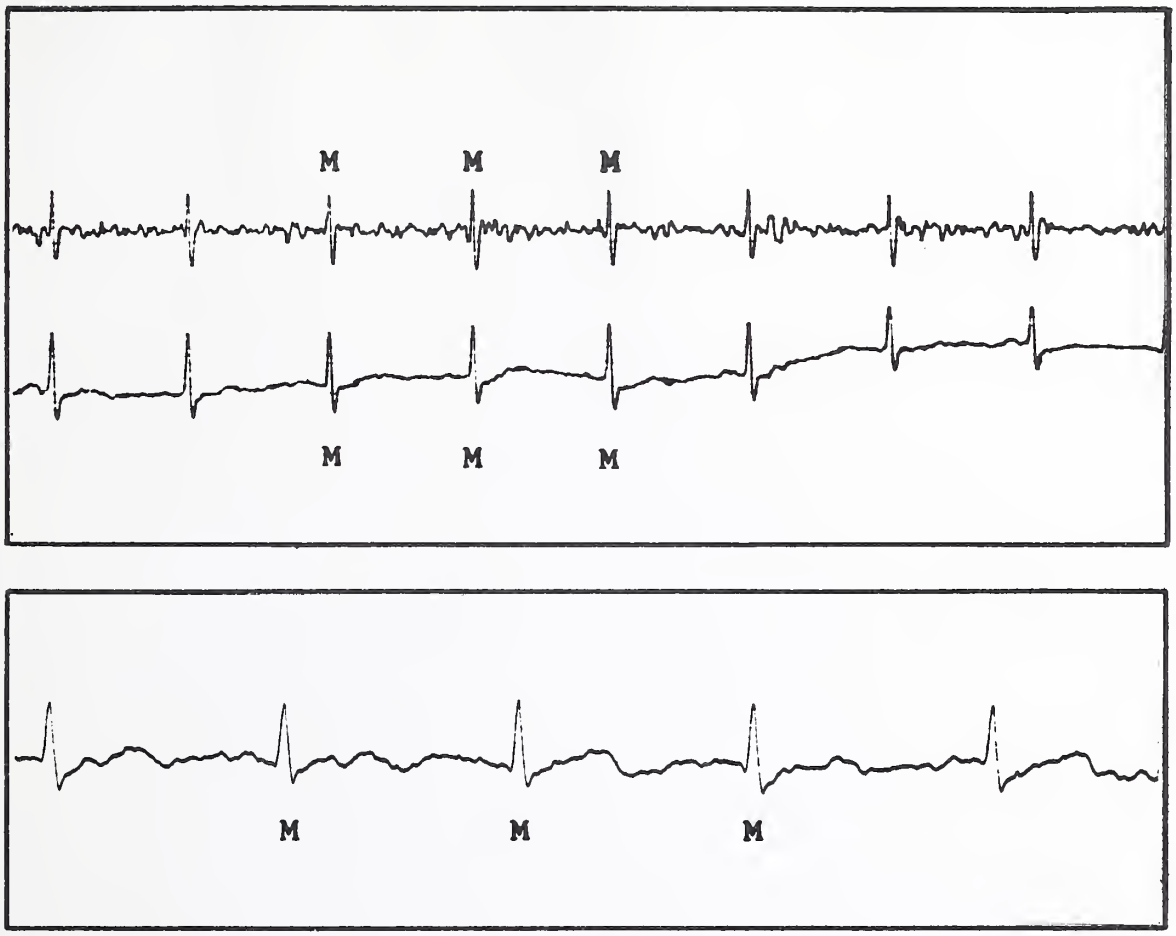

Figure 6B Tracings indicative of fetal death where other methods were inadequate for diagnosis.

D 56-1102 18 weeks gestation
E 57-0218 41 weeks gestation

56-1109 (Figure 7A, Tracing B, Page 48). At the time of admission to the hospital the patient was 20 weeks pregnant and had been bleeding for two months. No fetal heart could be heard, and fetal death was suspected. A fetal electrocardiogram was readily obtained and fetal life definitely established. An attempt was therefore made to stop the labor which was just beginning; this was unsuccessful and the next day the patient delivered a non-macerated stillborn.

57-0222 (Figure 7B, Tracing C, Page 49). This patient was 23 weeks pregnant and there was some question of a probable Cushings syndrome. The fetal heart could not be heard and in view of the hypertension, fetal death was seriously considered. A good fetal electrocardiogram tracing was obtained and to date the pregnancy is still intact.

57-0302 (Figure 7B, Tracing D, Page 49). This patient's gestation was of 19 weeks duration and she was admitted to the hospital for sudden blindness in one eye. The possibility of emboli coming from the placenta was entertained and the inability to hear the fetal heart raised a serious question as to fetal viability. A normal fetal electrocardiogram was recorded and

the pregnancy has continued uneventfully. For a short interval during recording the fetal rate became very slow; this finding is discussed in detail later in this study.

56-0803 (Figure 7B, Tracing E). This patient had been bleeding for five weeks prior to admission to the hospital. At that time, she was 18 weeks pregnant and had increasing flow. The fetal heart could not be heard and a clinical diagnosis of "fetal death" was made. Further diagnostic studies with the fetal electrocardiograph definitely revealed fetal life and the working diagnosis was then changed to threatened abortion. After three days in the hospital the bleeding subsided and the patient was discharged. Two weeks later the patient went into labor at home, the umbilical cord prolapsed and before the patient reached the hospital a small non-macerated stillborn infant was delivered.

Multiple Pregnancy. In our limited experience the fetal electrocardiogram has been valuable in confirming a clinical impression of multiple pregnancy. However, there have been at least two instances where a diagnosis of multiple pregnancy was not suspected. The patients were being

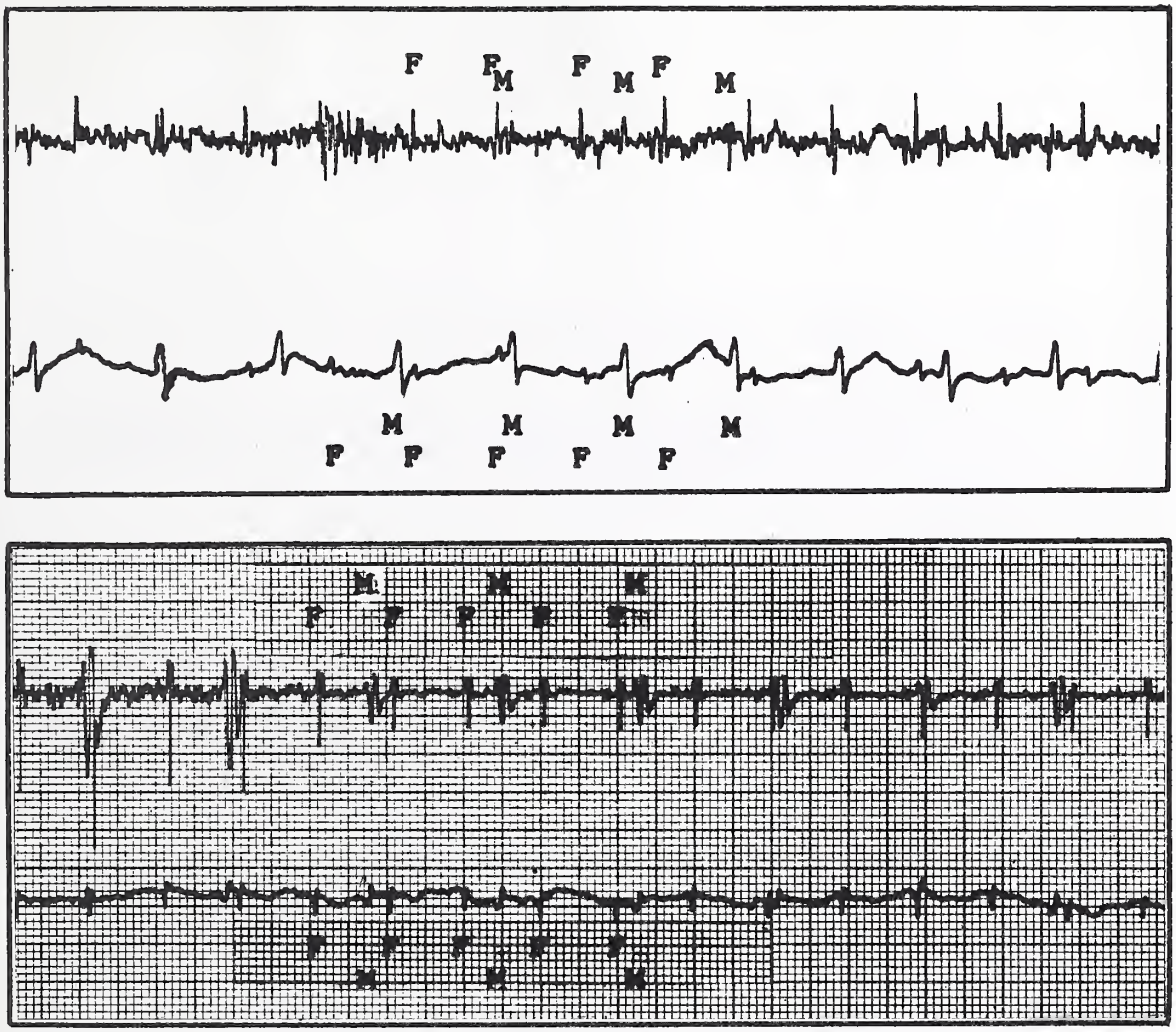

Figure 7A Tracings indicative of fetal life where other methods were inadequate for diagnosis.

A 57-0221 41 weeks gestation
B 56-1109 20 weeks gestation

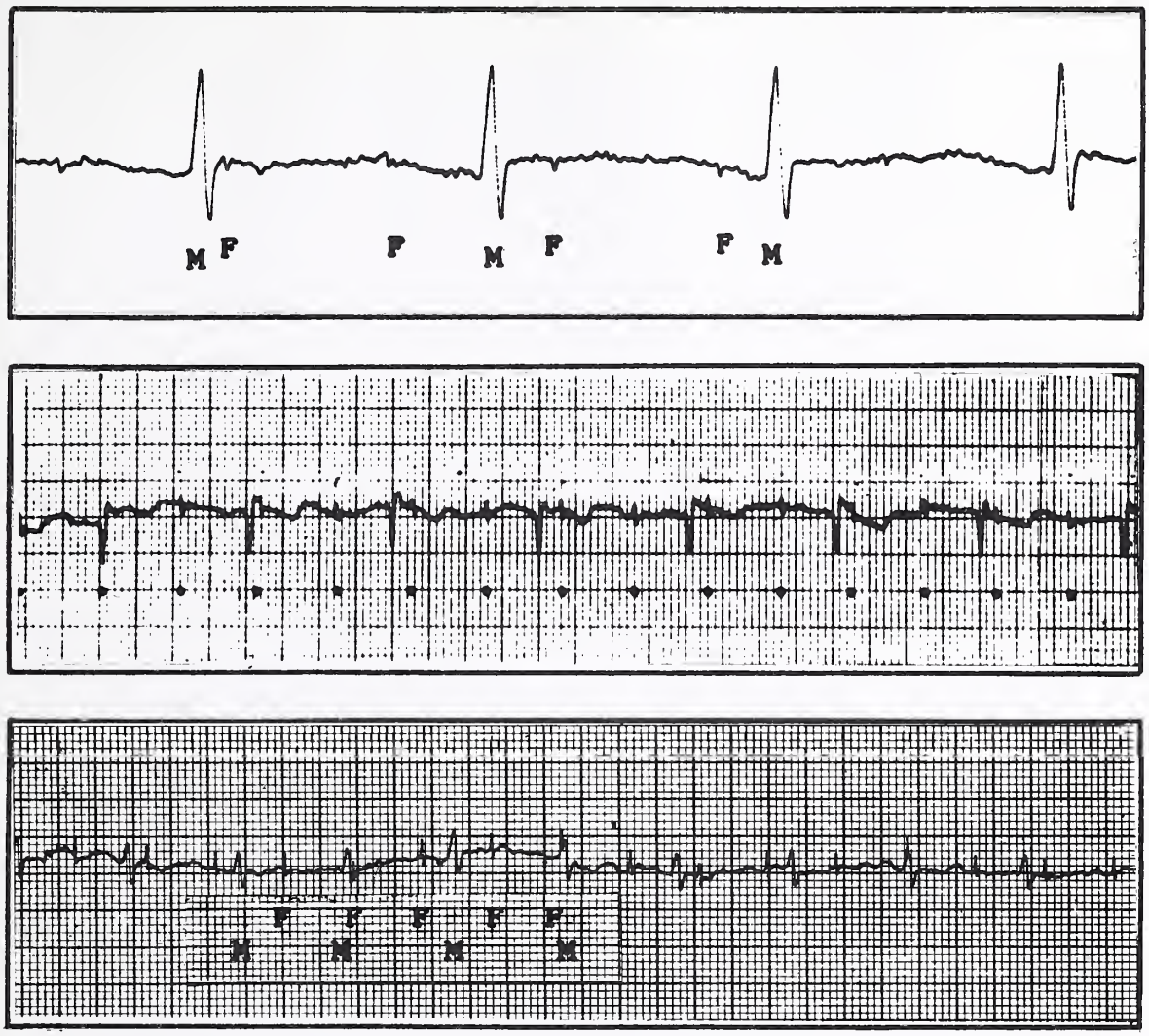

Figure 7B Tracings indicative of fetal life where other methods were inadequate for diagnosis

C 57-0222 23 weeks gestation
D 57-0302 19 weeks gestation
E 56-0803 18 weeks gestation

routinely checked during labor when multiple electrocardiograms were observed. In each instance, the diagnosis of twins before the patient was sent to the delivery room aided in the management.

57-0321 (Figure 8, Tracing A). This patient was a 26 weeks gestation in whom only one fetal heart was heard. The uterus was larger than would be expected in a single pregnancy. No x-ray had been taken; and the attending obstetrician thought he could palpate two fetal skulls. The tracing showed two independent sets of fetal complexes.

57-0209 (Figure 8, Tracing B). The gestation in this instance was of 17 weeks duration and because of the rapid growth of the uterus the patient's physician entertained the possibility of multiple pregnancy or hydatidiform mole. It was too early to hear the fetal heart or to establish a definite diagnosis with x-ray. The hazards of radiation to a young fetus also mitigated against the last diagnostic procedure. Although this was quite early in pregnancy it was decided to use the fetal electrocardiograph and the tracing revealed two fetal electrocardiograms, thus providing a positive diagnosis of multiple pregnancy and relieving the minds of both physician and patient.

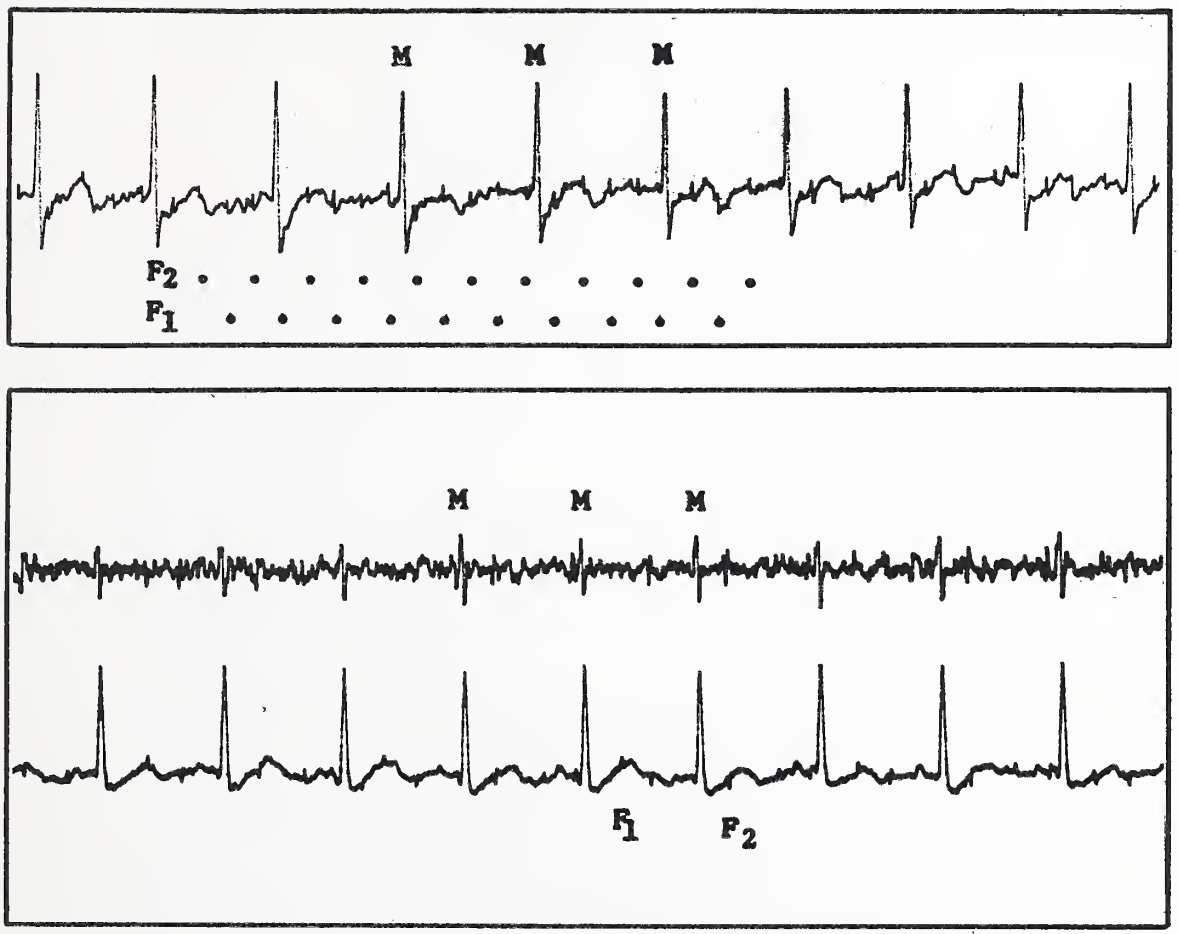

Figure 8 Tracings demonstrating the value of the fetal electrocardiogram in diagnosing multiple pregnancies.

A 57-0321 26 weeks gestation in which only one fetal heart was heard. Uterus was larger than normal.

B 57-0209 17 weeks gestation in which no fetal heart was heard in a rapidly enlarging uterus.

Presentation of the Fetus. In the general course of the work it has been noted that electrode positioning has a definite effect on the polarity of the fetal electrocardiogram, and that this polarity is more related to electrode positioning than to the presentation of the fetus. This is of some interest as prior reports have suggested that concordant fetal and maternal electrocardiograms are diagnostic of breech and discordant complexes of vertex presentation.

57-0216 (Figure 9) illustrates the tracings made on a vertex presentation which had been x-rayed for pelvimetry. The patient was a 39 weeks gestation, and subsequently delivered by vertex presentation.

In Tracing A it is readily seen that the complexes are concordant when the electrodes are placed in the LUQ and RLQ. If the electrodes were moved to the RUQ and LLQ, as in tracing B, the fetal and maternal complexes became discordant. It is obvious therefore, that the polarity of fetal electrocardiograms cannot be used to determine accurately fetal presentation.

Configuration of the Fetal Electrocardiogram. The configuration of the normal fetal electrocardiogram as recorded from the abdominal wall of the mother, is not known.

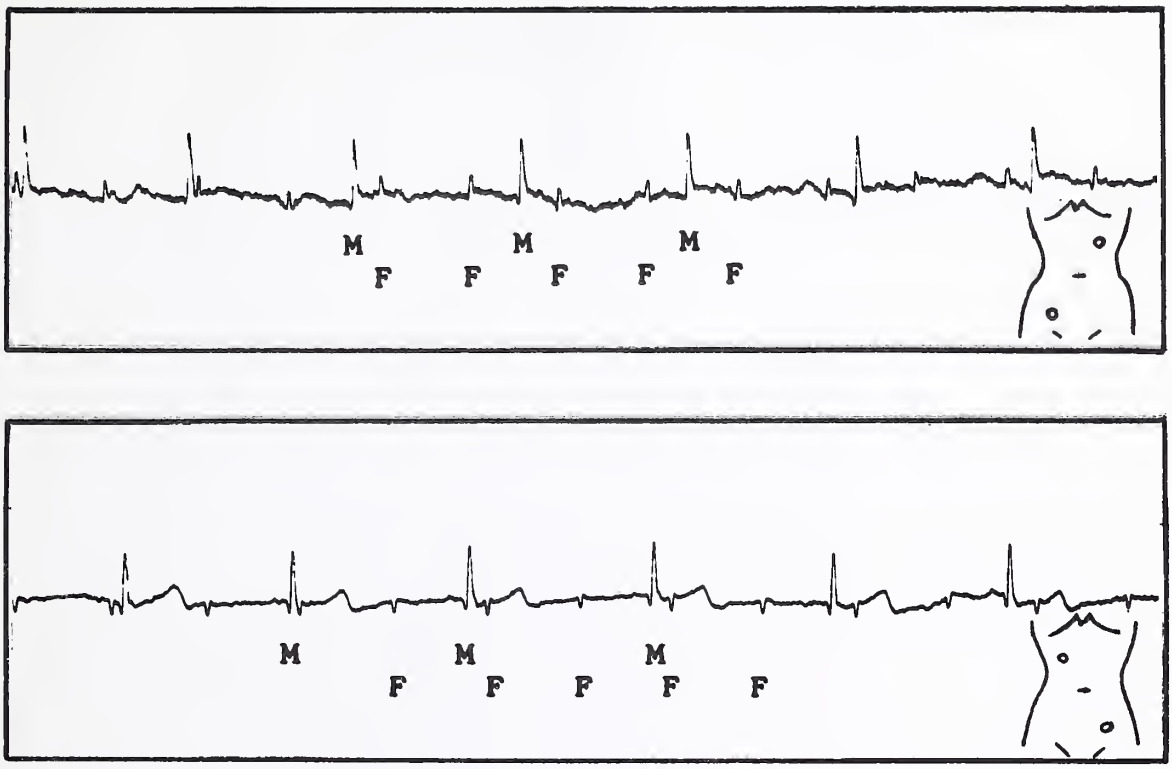

Figure 9 Tracings taken from the anterior abdominal wall of a 39 weeks gestation, with vertex presentation, showing that the relation of the fetal complex to the maternal complex is dependent upon the placement of the electrodes.

A 57-0216 Electrodes at the LUQ and RLQ
B 57-0216 Electrodes at the RUQ and LLQ

This is primarily due to the low level signals involved, and the limitation of present electronic sensing devices. As yet, no attempt has been made to study specifically fetal electrocardiogram configurations. However, some interesting and provocative findings have been noted.

56-0802 (Figure 10, Tracing A, Page 56). This tracing was taken during labor on a patient at term. The fetal heart rate fell within the accepted limits of normal but definite notching was noted in the fetal electrocardiogram. The delivery was uneventful and resulted in a normal full term infant who cried spontaneously. The significance of any of these findings is not known.

57-0212 (Figure 10, Tracing B, Page 56). This tracing was recorded in a term labor at three to four centimeters of dilatation. Contractions were strong and regular and the fetal heart rate and rhythm appeared normal. However, the duration of the fetal QRS complex was greater than we had previously observed. Since the clinical status of both mother and fetus appeared normal this finding was noted with some interest but no conclusions could be drawn. Unfortunately, no further tracings were made on this patient, as the equipment

was required for a patient that was bleeding. Four hours later the patient delivered a flaccid infant which breathed momentarily and expired. At the time of delivery, the separated placenta was found in the uterus, which was filled with about 1500 cubic centimeters of free blood and some recent clots. Whether the increased duration of the fetal QRS complex indicated early difficulty is not known.

56-0905 (Figure 10, Tracing C). The patient from whom this tracing was made was in labor at term. About three weeks earlier, the fetal heart rate was noted to be between 30 and 35 beats per minute. The fetal electrocardiogram shows a heart rate of 32 beats per minute with a marked S-T segment followed by a large T wave. This is the first instance where such profound fetal electrocardiogram changes have been reported. Because of heavy bleeding just prior to delivery, the fetus died. Death was judged to be due to the trauma of delivery, and not directly related to the bleeding. At autopsy, no gross or microscopic myocardial abnormalities were noted. Because of marked subcutaneous edema, enlarged liver, and spleen, with many areas of extra-medullary hematopoiesis, a pathological

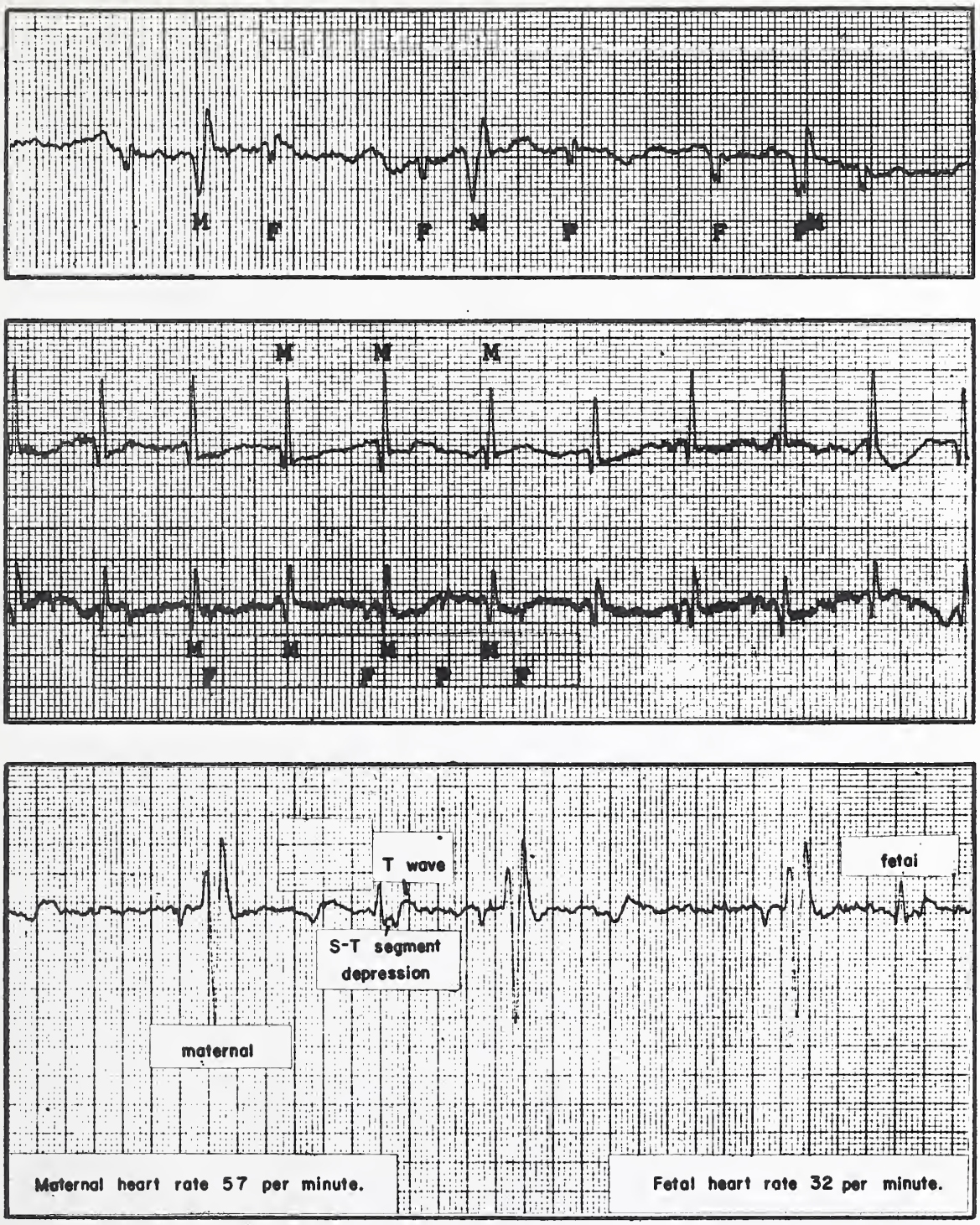

Figure 10 Abnormal fetal electrocardiogram configurations

A 56-0802 Notched fetal QRS complex in a normal full term infant.

B 57-0212 Increased duration of the fetal QRS complex in a full term infant.

C 56-0905 Abnormal S-T segment and large T wave. Diagnosis of hydrops fetalis at autopsy.

diagnosis of "hydrops fetalis" was made. There was no laboratory evidence of Rh incompatibility and the possibility of AB incompatibility was suspected.

Although this case does not permit any conclusions, it is exciting to reflect on the possibility that fetal pathological physiology may be reflected by abnormal fetal electrocardiogram changes, thereby providing some means of assessing fetal environment in Rh incompatibility, diabetes mellitus, toxemia of pregnancy, and other conditions where the stillborn rate increases with prolongation of pregnancy. If it could be determined that a fetus were in an unfavorable environment, immediate termination of pregnancy might increase fetal salvage.

Fetal Bradycardia. The significance of fetal bradycardia before the onset of labor is not known. Many physicians have reported transitory fetal bradycardia during routine prenatal examination but no recordings have been made of this phenomenon. Figure 11 shows a tracing made on patient 57-0302, who was being studied for fetal viability, and whose history has been given previously under that subheading. From the tracings it is readily seen that there is a gradual prolongation of the interval between fetal

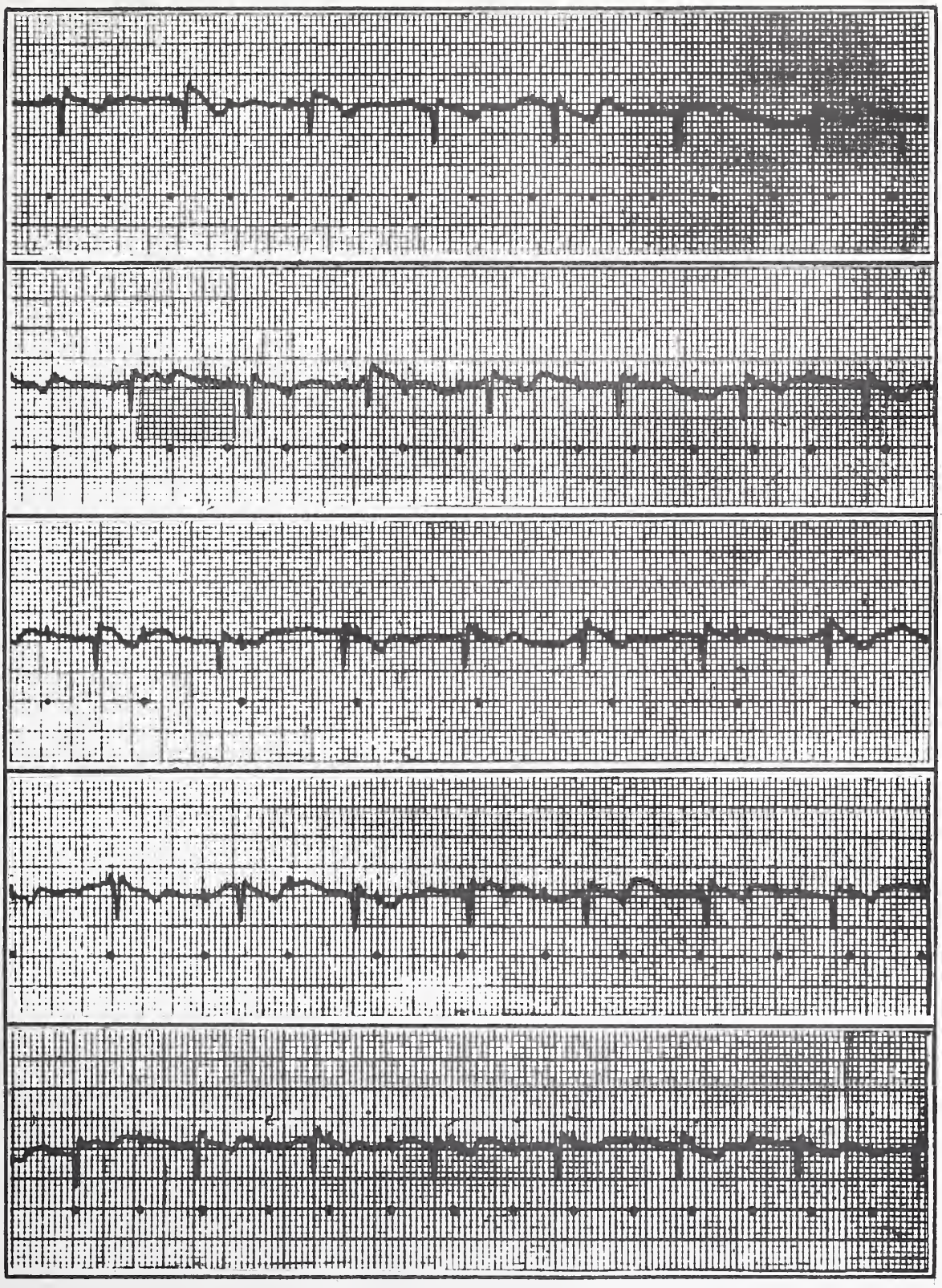

Figure 11 Marked fetal bradycardia in a 19 weeks gestation. Patient not in labor. 57-0302

pulses, and the graph of the instantaneous fetal heart rate (Figure 12) clearly indicates that the rate varied from 160 to 70 beats per minute. This is being reported as a documented clinical finding and no attempt is being made to interpret its significance.

Miscellaneous. During the routine study of fetal heart rate and rhythm, two instances were found where transitory rapid pulses of electrical energy were detected. Both instances concerned abnormal obstetrical conditions. As far as can be determined, they are not due to outside electrical interference, technical difficulties or maternal activity.

57-0210 (Figure 13, Tracing A, Page 62). This recording was made from a patient who was 28 weeks pregnant and who had been bleeding intermittently for two months. At the time of recording she had a hemoglobin of seven and one half grams. The fetal heart rate when checked with the stethoscope and the fetal electrocardiogram was between 150 and 100 beats per minute. Sporadic bursts of rapid electrical impulses lasting two to three minutes were noted. At these times, the fetal heart rate was found to be within the range given above, when checked stethoscopically. Following transfusion, another unsuccessful attempt was made to

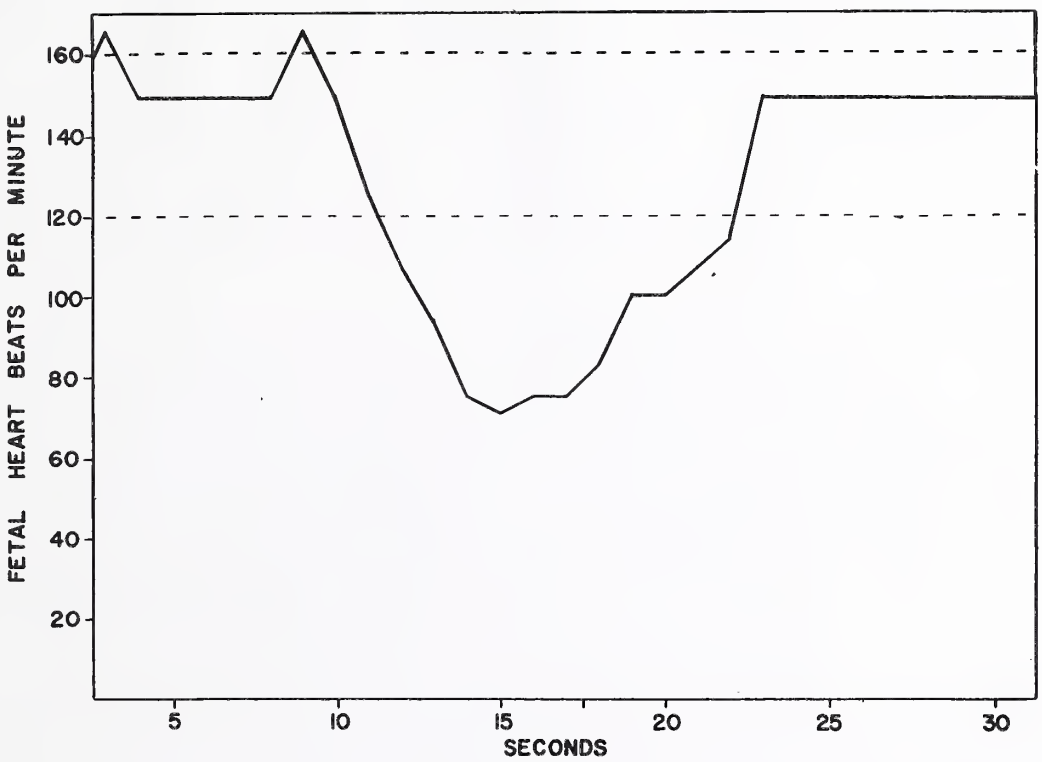

Figure 12 Graph showing momentary drop in the fetal heart rate as demonstrated in the tracings shown in Figure 11. This illustrates the value of continuous monitoring of the fetal heart, because such a sudden and transient decrease in the rate might easily be overlooked with the usual auscultatory methods. The usually accepted "normal range" of 120-160 beats per minute is indicated by the dotted lines on the graph.

record similar activity. Because of continued bleeding an emergency Caesarean section was done and premature separation of the placenta found. A normal 1795 gram infant was delivered.

56-1110 (Figure 13, Tracing B). Similar sporadic bursts of rapid electrical activity were noted in this 26 week gestation. Clinically, the patient was preeclamptic and had polyhydramnios. At the time of recording, definite fetal life was detected. However, two days later, a stillborn erythroblastotic infant was delivered.

It is interesting to note that in both these cases, the rate of the impulses was approximately 300 per minute. These rather unexpected and baffling findings are reported as a matter of interest and serve to emphasize our very limited knowledge of fetal physiology.

Fetal Heart Rate Studies During Labor.

The foregoing results may be considered auxiliary to the broader problem of the significance of fetal heart rate and rhythm during labor. Studies in this area are of necessity planned on a long term basis and although approximately 150 hours of complete labors have been recorded, no conclusions can be reached. However, it is already evident that the

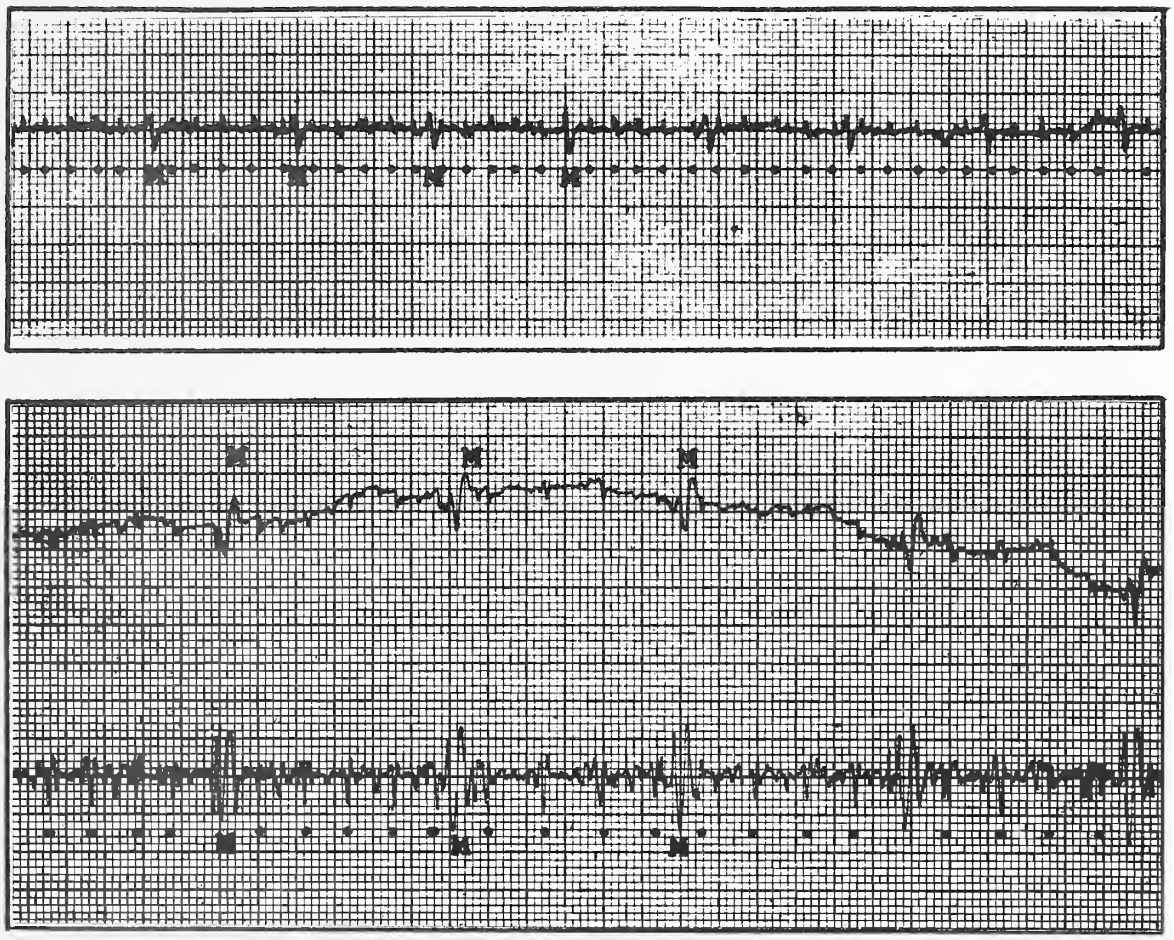

Figure 13 Tracings illustrating rapid impulses of unknown significance occurring in women whose gestations were complicated by abnormal obstetrical conditions.

A 57-0210 28 weeks gestation
B 56-1110 26 weeks gestation

present clinical definition of "fetal distress" in terms of fetal bradycardia and arrhythmia needs clearer definition.

Figure 14 is a graph of the instantaneous heart rate of a fetus (vertex presentation) in early labor and indicates that the cardiac rate and rhythm are relatively unaffected by a uterine contraction. Figure 15 shows the fetal heart rate in the same patient in late labor when the cervix was seven centimeters dilated. There is now a marked slowing of the fetal heart rate to 70 beats per minute at the height of a contraction and a rapid return to pre-contraction levels.

Current obstetrical teaching suggests that a fetal bradycardia of less than 100 beats per minute is indicative of "fetal distress". In this case a vigorous healthy infant was delivered.

Figure 16 (page 65) is a graph of the fetal heart rate during a contraction in late labor with a breech presentation. Here the heart rate is relatively unaffected by a contraction and is at variance with the finding under similar conditions in vertex presentation. One would expect a similar drop in late labor as found in vertex presentation if the bradycardia in the latter instance is due to the production of transitory fetal hypoxia by the contracting uterus. The different findings in vertex and breech presentations suggest that other mechanisms may be operating.

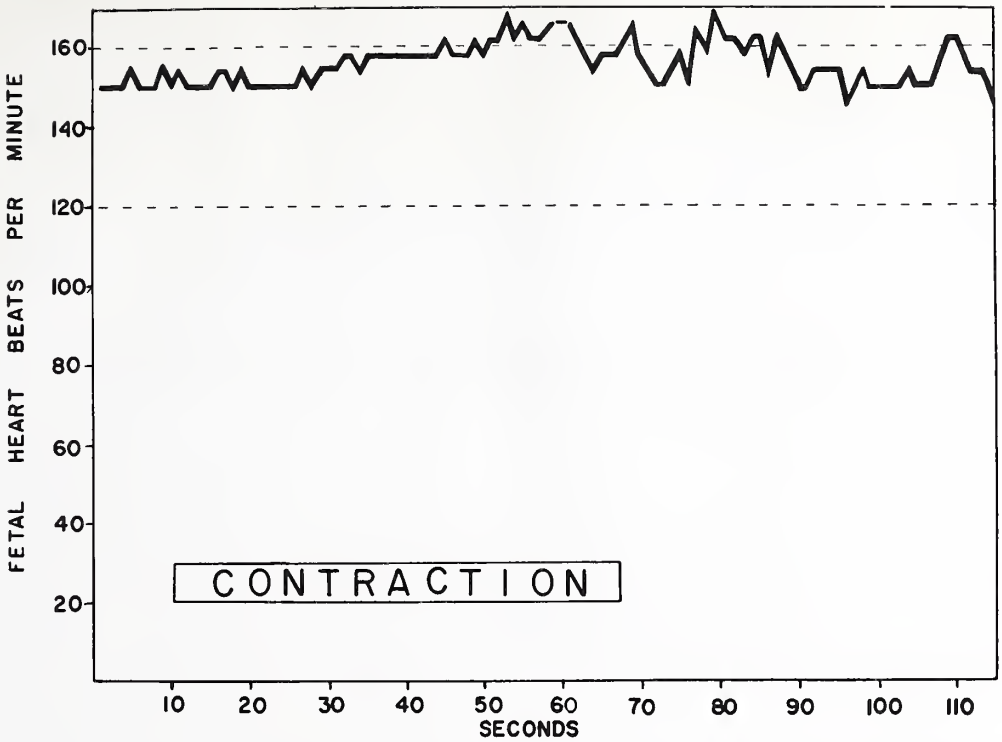

"Normal" fetal heart rate in early labor. Primigravida, 2 cms.

Figure 14

Normal fetal heart rate in late labor. Primigravida, 7 cms.

Figure 15

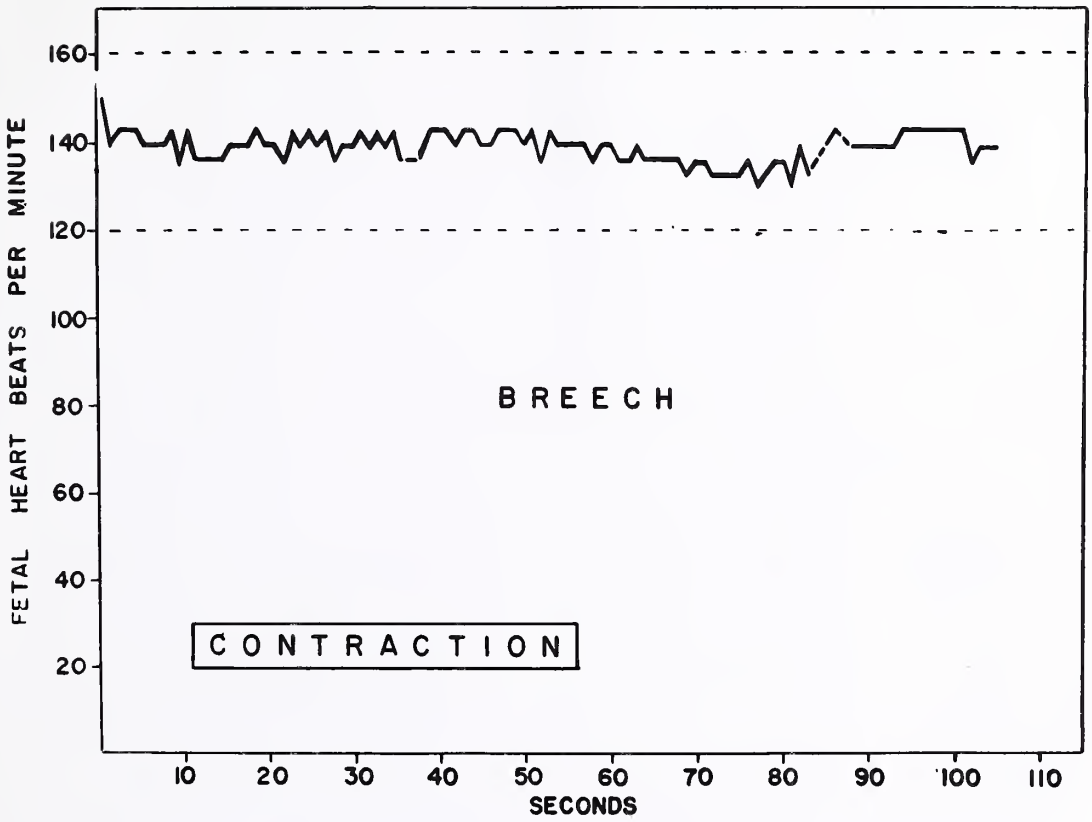

"Normal" fetal heart rate in late labor. Primigravida, 7 cms.

Figure 16

A number of bleeding patients have been studied during labor but so far no abnormalities of fetal cardiac rate and rhythm have been noted, and in each instance the infant appeared to be normal.

DISCUSSION

DISCUSSION

From this limited clinical trial with equipment specially designed for the study of fetal energy, it is apparent that fetal viability can be determined quite readily. The ability to diagnose fetal viability in second trimester gestations provides the clinician with a safe technique which gives definitive clinical information not available by other procedures. This is especially valuable in the various disturbances of pregnancy where excessive bleeding endangers the life of the patient and it is not possible to determine accurately the fetal status. It is equally valuable where a rapidly enlarging uterus suggests the possibility of multiple pregnancy or hydatidiform mole. During the course of labor, the fetal heart sometimes becomes unobtainable by routine auscultatory methods. In all of these situations, a fetal electrocardiogram tracing is very reassuring, and provide the obstetrician with an objective measurement of fetal status.

Further study may elucidate the meaning of abnormal fetal electrocardiogram configurations, fasts bursts of impulses, and aberrations in rate and rhythm. Although the significance of these findings is not known, there is a strong suggestion that they may indicate pathologic fetal

physiology, and may therefore suggest an opportune time to remove the fetus from an unfavorable environment.

The importance of fetal heart rate and rhythm studies during labor is relatively well established. If the current clinical criteria of fetal distress (fetal bradycardia less than 100 beats per minute and fetal cardiac arrythymias) is used as an index for intervention during the course of labor, the perinatal mortality and morbidity is substantially less than if these findings are ignored. Labor is a very hazardous period in the life of the fetus, and if equipment is available for continuous monitoring of the fetal heart rate and rhythm, it is probable that both perinatal mortality and morbidity will be further reduced.

In order to define more adequately these criteria, a large number of labors will have to be studied carefully. The major problem here is the great volume of data to be acquired and reduced.

Work to date in this area suggests that the currently accepted definitions of normal fetal cardiac rate and fetal distress are open to some question. If these limits can be defined more accurately, some form of continuous monitoring system could be fitted to each patient in labor so that abnormal deviations would be immediately detected. Such an instrument has already been developed and used in current experimental work.

SUMMARY AND CONCLUSIONS

SUMMARY AND CONCLUSIONS

1. The use of equipment specially designed for the investigation of fetal energy suggests that studies of fetal physiology may be accelerated with modern electronic instrumentation methods.

2. The fetal electrocardiogram is valuable for the diagnosis of fetal viability in second and third trimester pregnancies when the more conventional techniques are inadequate.

3. When the fetal electrocardiogram is separated from the maternal electrocardiogram, a means is available to follow the fetal heart rate and rhythm throughout labor.

4. Fetal electrocardiographic configuration changes may reflect pathologic fetal physiology.

5. Current criteria for normal fetal heart rate and "fetal distress" may be subject to revision in the light of studies done with objective techniques.

BIBLIOGRAPHY

BIBLIOGRAPHY

1. Gunn, A.L. and Wood, M.C.: The amplification and recording of fetal heart sounds. Proc. Royal Soc. Med., 46:85, 1953.

2. Pommerenke, W.T. and Bishop, F.W.: Amplification of fetal heart sounds. Am. J. Obst. & Gynec., 35:851, 1938.

3. Hyman, A.S.: Irregularities of the fetal heart. Am. J. Obst. & Gynec., 20:332, 1930.

4. Burnham, L.: An unusual irregularity of the fetal heart during pregnancy. Am. J. Obst. & Gynec., 37:164, 1939.

5. Lund, C.J.: Recognition and treatment of fetal heart arrhythmias due to anoxia. Am. J. Obst. & Gynec., 40:946, 1940.

6. Smith, A.L. and Hervert, W.J.: A method for recording and reproducing fetal heart sounds. Am. J. Obst. & Gynec., 40:102, 1940.

7. Smith, A.L.: Stethogram and recorded disc of fetal heart sounds in a twin pregnancy. Am. J. Obst. & Gynec. 42:908, 1941.

8. Dressler, M. and Moskowitz, S.N.: Fetal electrocardiography and stethography. Am. J. Obst. & Gynec., 41:775, 1941.

9. Steer, C.M. and Hertsch, G.J.: Continuous observation of the fetal heart. Am. J. Obst. & Gynec., 62:1139, 1951.

10. Lund, C.J.: Fetal tachycardia during labor. Am. J. Obst. & Gynec. 45:636, 1943.

11. Sankey, A.O.: Congenital heart disease simulating foetal distress--two cases. Brit. Med. J., 4579:676, 1948.

12. Abraham, L.M. and Dyer, I.: Significance of fetal heart rate in pregnancy and labor. New Orleans Med. & Surg. J., 102:245, 1949.

13. Hoff, E.C., Kramer, T.C., DuBois, D. and Patten, B.M.: The development of the electrocardiogram of the embryonic heart. Am. Heart J., 14:470, 1939.

14. Lindsley, D.B.: Heart and brain potentials of human fetuses in utero. Am. J. Psychol., 55:412, 1942.

15. Patten, B.M.: Micromoving pictures and electrocardiographic records of age changes in embryonic heart action. West. J. Surg., 52:325, 1944.

16. Arey, L.B.: Developmental Anatomy. ed. 5, Philadelphia, 1946, W.B. Saunders Company, p. 332.

17. Krumbhaar, E.B.: Electrocardiographic studies in normal infants. Am. J. Physiol., 40:133, 1916.

18. Easby, M.H.: Electrocardiograms from a four and one half months old fetus. Am. Heart J., 10:118, 1934.

19. Heard, J.D., Burkley, G.G., and Schaeffer, C.R.: Electrocardiograms derived from eleven fetuses through the medium of direct leads. Am. Heart J., 11:41, 1936.

20. Ward, J.W. and Kennedy, J.A.: The recording of the fetal electrocardiogram. Am. Heart J., 23:64, 1942.

21. Vara, P. and Niemineva, K.: On electrocardiograms taken directly from the human foetus in utero. Gynaecologica, 132:241, 1951.

22. Mann, H. and Mayer, M.D.: The uterine electrocardiogram. J. Mt. Sinai Hosp., 8:805, 1942.

23. Mann, H. and Bernstein, P.: Fetal electrocardiography. Am. Heart J., 22:390, 1941.

24. Southern, E.M.: Electrocardiography and phonocardiography of the foetal heart. J. Obst. & Gynec. Brit. Emp., 61:231, 1954.

25. Strassmann, E.O.: The fetal electrocardiogram late in pregnancy. Proc. Staff Meet., Mayo Clin., 11:778, 1936.

26. Strassmann, E.O.: Life or death of the fetus--a new graphic test in pregnancy. Surg., Gynec. & Obst., 67:826, 1938.

27. Strassmann, E.O. and Mussey, R.D.: Technic and results of routine fetal electrocardiography during pregnancy. Am. J. Obst. & Gynec., 36:986, 1938.

28. Bell, G.H.: The human foetal electrocardiogram. J. Obst. & Gynec. Brit. Emp., 45:802, 1938.

29. Bernstein, P.: Gastroschisis--A rare teratological condition in the newborn. Arch. Pediatrics, 57:505, 1940.

30. Geiger, A.J., Monroe, W.M., and Goodyer, V.N.A.: Clinical fetal electrocardiography--practical accomplishment. Proc. Soc. Exper. Biol. & Med., 48:646, 1941.

31. Monroe, W.M.: Clinical fetal electrocardiography. Thesis. Yale University, 1941.

32. Goodyer, V.N.A., Geiger, A.J. and Monroe, W.M: Clinical fetal electrocardiography. Yale J. Biol. & Med. 15:1, 1942.

33. Goodyer, V.N.A.: Clinical prenatal electrocardiography. Thesis. Yale University, 1942.

34. Vara, P. and Halminen, E.: On fetal electrocardiography. Acta. Obst. et Gynec. Scandinav., 26:249, 1946.

35. Mann, H.: A new portable electrocardiograph. Proc. Soc. Exp. Biol. & Med., 23:19, 1925.

36. Mann, H.: A light weight portable electrocardiograph. Am. Heart J., 7:6, 1932.

37. Bernstein, P. and Mann, H.: Clinical evaluation of fetal electrocardiography--100 cases by a new technique and improved instrument. Am. J. Obst. & Gynec., 43:21, 1942.

38. Paley, S.S. and Krell, S.: Fetal electrocardiography and stethography. Am. J. Obst. & Gynec., 48:489, 1944.

39. Plant, R.K. and Steven, R.A.: Complete A-V block in a fetus. Am. Heart J., 30:615, 1945.

40. Vara, P. and Halminen, E.: On foetal electrocardiography II. Acta Obst. et Gynec. Scandinav., 31:179, 1951-1952.

41. Blondheim, S.H.: The technique of fetal electrocardiography. Am. Heart J., 34:35, 1947.

42. Thoms, H.: The technique of fetal electrocardiography [Review of Blondheim's article--reference 41] Quart. Rev. of Obst. & Gynec., 6:316, 1948.

43. Pfister, C.W. and Plice, S.G.: A method for fetal electrocardiography. Am. Pract. & Digest. Treat., 1:816, 1950.

44. Smyth, C.N.: Experimental electrocardiography of the foetus. Lancet, 264-2:1124, 1953.

45. Southern, E.M.: Fetal anoxia and its possible relation to changes in the prenatal fetal electrocardiogram. Am. J. Obst. & Gynec., 73:233, 1957.

46. Davis, J. and Meares, S.D.: Preliminary report on an investigation of foetal electrocardiography and fetal stethography. Med. J. of Australia, 2:501, 1954.

47. Perell, A.: Investigation of fetal electrocardiography and stethography [Review of article by Davis and Meares--reference 46]. Am. J. Obst. & Gynec., 70:1154, 1955.

48. Bernstine, R.L. and Berkowski, W.J.: Prenatal fetal electrocardiography. Am. J. Obst. & Gynec., 70:631, 1955.

49. Annual Report: Department of Health, Education and Welfare, Washington, D.C. 1955.

50. Bieber, G.F.: Review of 353 cases of premature separation of the placenta. Am. J. Obst & Gynec., 65:257, 1953.

51. FitzGerald, T.B. and McFarlane, C.N.: Foetal distress and intrapartum foetal death. Brit. Med. J., 2:358, 1955.

52. Tarnower, H. and Lattin, B.: Tachycardia in the newborn. New York J. Med., 42:805, 1942.

53. Katz, L.N.: Electrocardiography. Philadelphia, 1941, Lea and Febiger, p. 131.

Date Due

Demco 293-5

T113
Y12
2090